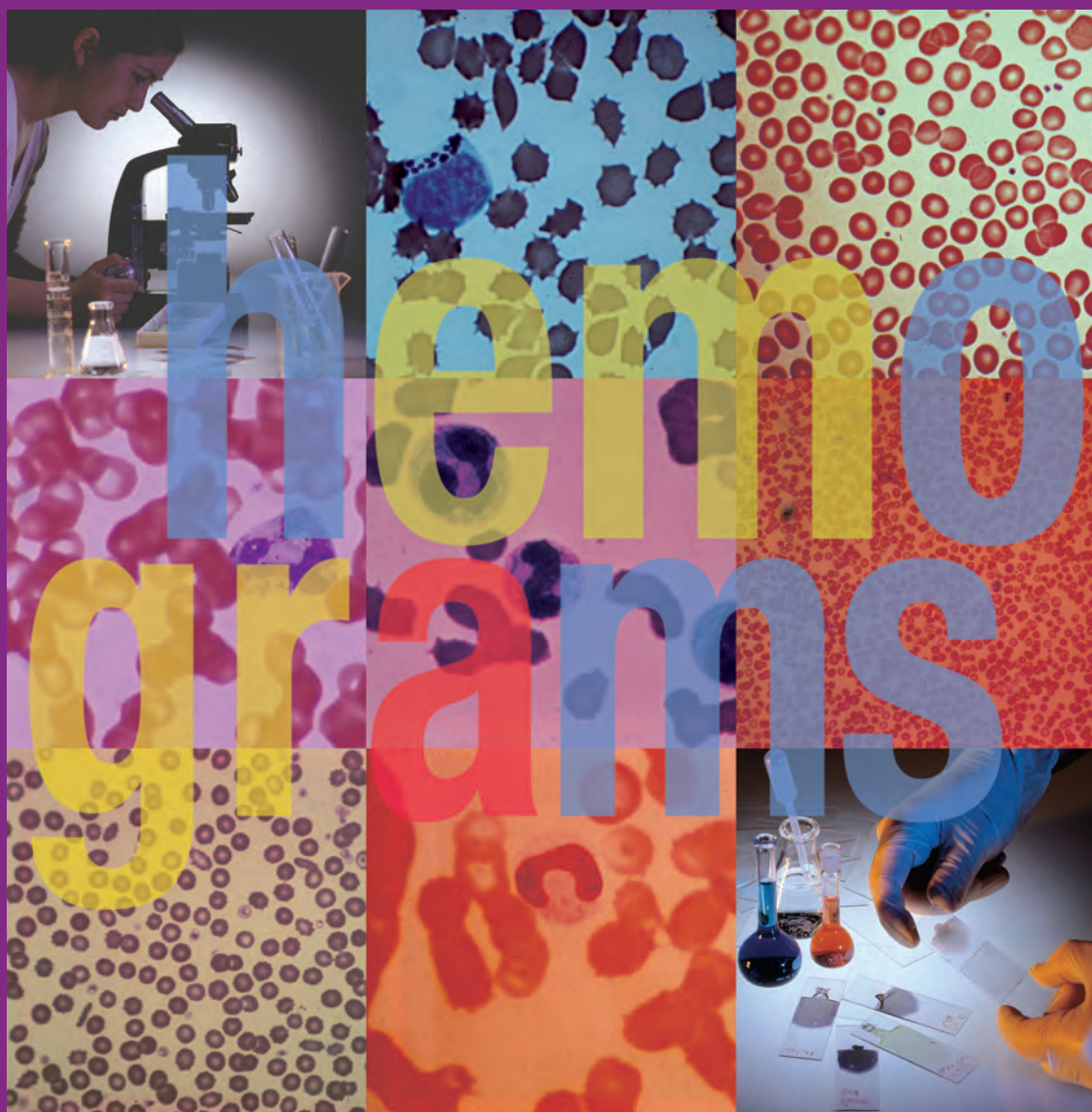

\$50.00

# Hemogram Interpretation for Dogs and Cats

*Alan H. Rebar, DVM, PhD*

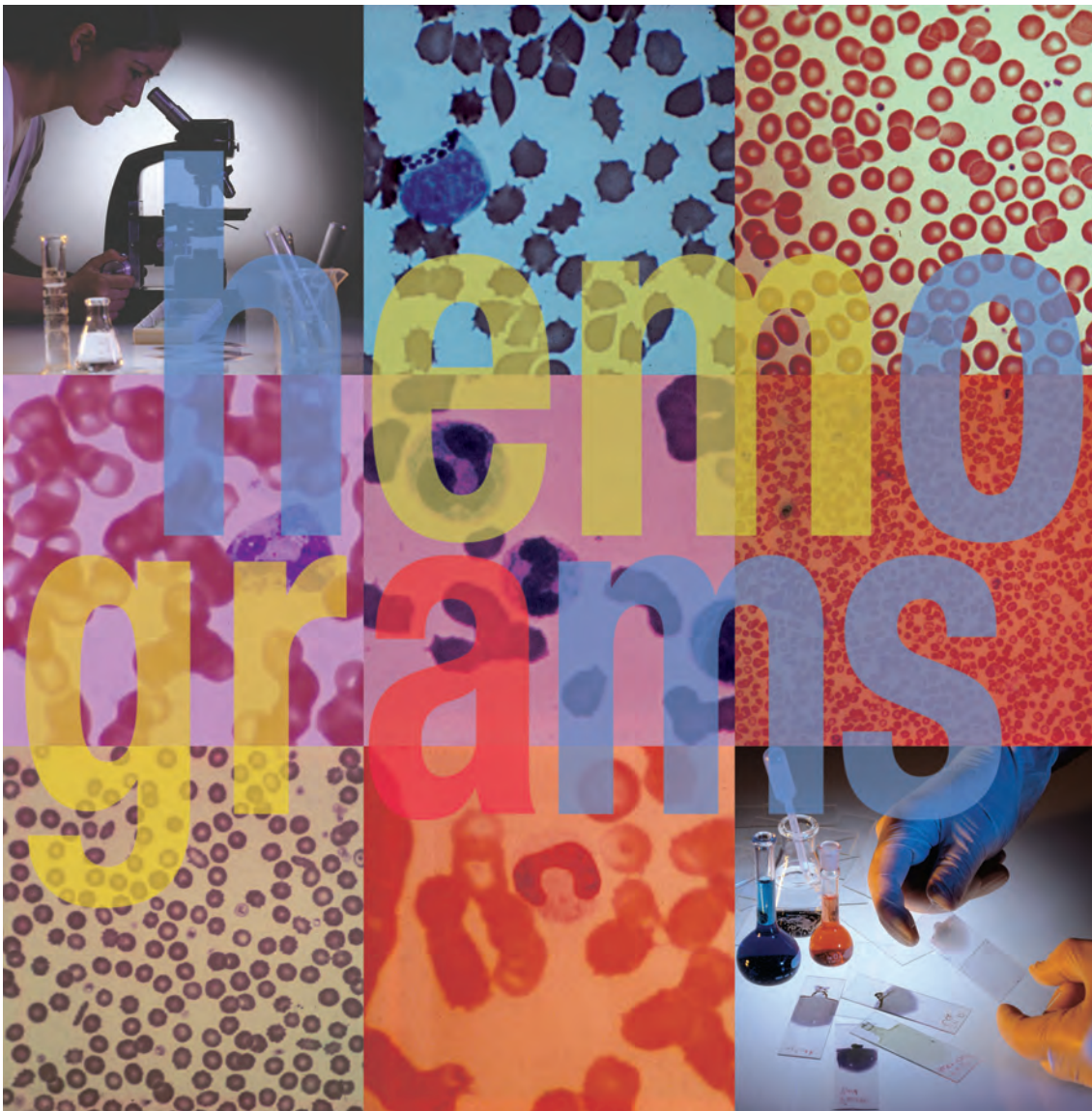

Nestlé PURINA

Clinical Handbook Series

# Hemogram Interpretation for Dogs and Cats

*Alan H. Rebar, DVM, PhD*



Nestlé PURINA

Clinical Handbook Series

Published by The Gloyd Group, Inc.

Wilmington, Delaware

© 2004 by Nestlé Purina PetCare Company.

All rights reserved.

Printed in the United States of America.

Nestlé Purina PetCare Company: Checkerboard Square, Saint Louis, Missouri, 63188

First printing, 1998.

*Laboratory slides reproduced by permission of Alan Rebar, DVM, PhD.*

*Photographs by Terence Roberts Photography.*

This book is protected by copyright.

ISBN 0-9678005-1-X

# Table of Contents



Introduction.....1

## Part I

### Chapter 1

*Leukocytes in Health & Disease* .....4

### Chapter 2

*Erythrocytes in Health & Disease* .....15

### Chapter 3

*Platelets in Health & Disease* .....27

## Part II

### Chapter 4

*Hemogram Interpretation*.....33

### Chapter 5

*Case Studies* .....39

## Part III

#### *Table 1.*

*Hematological Reference Ranges of the  
Dog and Cat* .....81

*Index of Figures* .....82

*Glossary of Terms* .....85

*Suggested Reading* .....87



# Introduction



This monograph, **Hemogram Interpretation for Dogs and Cats**, is divided into three parts. Part I is comprised of Chapters 1 through 3; Chapters 4 and 5 make up Part II. To maximize its usefulness, each chapter should be read and studied in sequence. Part III contains a variety of reference materials and other resources.

Part I (Chapters 1, 2, and 3) is designed to acquaint the reader with the basic physiology and pathophysiology of the hematopoietic system of the dog and cat. It is not intended as an in-depth treatise but rather focuses on those aspects of hematopoietic physiology which are most useful in understanding peripheral blood changes in disease.

Part II (Chapters 4 and 5) is designed to develop a systematic approach to the interpretation of peripheral blood data and morphology, and to afford the reader the opportunity to practice this approach on a series of actual clinical cases. Of necessity, there is some redundancy between Parts I and II; however, this redundancy will serve to reinforce the reader's understanding of hematologic pathophysiology and its relationship to hemogram interpretation.

Part III includes: **Table 1. Hematological Reference Ranges of the Dog and Cat** that lists normal blood values; a full **Index of Figures** that describes all the photographs of slides used in this book; a **Glossary of Terms** that contains definitions of those words which are underlined throughout the text; and, a comprehensive listing of **Suggested Reading** on the topic of canine and feline hematology.





# Chapter 1: Leukocytes in Health and Disease

## Overview

From a functional perspective, circulating leukocytes, or white blood cells (WBC), belong to two systems: the **phagocytic system** and the **immunocytic system**.

These two immune systems are functionally interdependent. The phagocytic system is comprised of the granulocytes and the monocyte/macrophage continuum. The immunocytic system is comprised of circulating T and B lymphocytes. Factors produced by monocytes/macrophages profoundly influence lymphocyte function and a variety of lymphocyte products, in turn, influence the function of the phagocytes.

The phagocytes (ie, granulocytes, monocyte/macrophage continuum) are the first line of defense against invading microorganisms; they are attracted to sites of infection and, by the process of phagocytosis, ingest and destroy bacteria and other agents on contact. Therefore, the phagocytes can be thought of as the **non-specific immune system**.

In contrast, the immunocytic system is the **specific immune system**. Its effector cells (ie, T and B lymphocytes) are responsible for both the production of **humoral immunity** in the form of antibodies directed against specific antigens as well as **cell-mediated immunity** in the form of specific cytokine production.

### Different Circulating Leukocytes Belong to Different Immune Systems

Non-specific Immune System	Specific Immune System
▼	▼
Phagocytic	Immunocytic
▼	▼
Granulocytes Monocytes/macrophages	B lymphocytes T lymphocytes

The following paragraphs explore the structure and function of each system in greater detail.

## The Phagocytic System

### The Phagocytic Process

The process of phagocytosis has been well studied and can be divided into several stages.

The initial stage is **chemotaxis**. In this early phase, all phagocytic cells are mobile and are being attracted to sites of inflammation and infection by an increasing gradient of small molecules known as chemotaxins. Among the most potent chemotaxins are:

- lipopolysaccharides (components of bacterial membranes),
- active fragments of complement,
- antigen-antibody complexes, and
- certain products of lymphocytes.

Once phagocytes have entered an area of inflammation and infection, they must adhere to the microorganism(s) in order for the process of phagocytosis to continue.

**Adherence** (stage II) occurs more readily if organisms have been opsonized; that is, coated by antibodies or complement fragments. Phagocytes have receptors on their surfaces for such opsonins which facilitates adherence. The process of **opsonization** represents one of the interactions between the non-specific and specific immune systems; antibodies are produced by immunocytes, phagocytes attach to those antibodies.

Next, adhered organisms must be **internalized** (stage III). This is accomplished by invagination of the superficial cell membrane and formation of a phagocytic vacuole around the organism. Almost simultaneously, the cytoskeletal and microtubular system of the cell moves the cytoplasmic granules towards the phagocytic vacuoles. Fusion of the respective membranes allows intimate contact between granule content and the microorganism, resulting in killing and digestion of the microorganism.

### The Stages of Phagocytosis

- I. Chemotaxis
- II. Adherence
- III. Internalization



## The Granulocytes

### Neutrophils

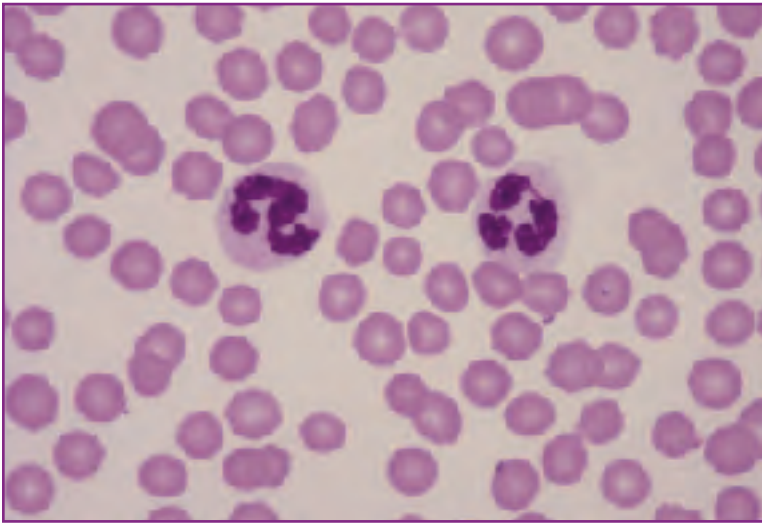
Neutrophils are the predominant circulating granulocyte and are easily distinguished on the peripheral blood film by the following morphologic characteristics (*Fig. 1*):

### Granulocytes

Neutrophils

Eosinophils

Basophils



**Fig. 1** Normal circulating neutrophils.

- round
- measure 12.0  $\mu$  to 15.0  $\mu$  in diameter
- abundant pale pink, granular cytoplasm
- lobed nuclei with deeply staining, condensed chromatin

This morphologic appearance provides significant clues regarding their functional state. The condensed, deeply stained chromatin suggests a mature nucleus with predominantly inactive heterochromatin. The pink, granular cytoplasm suggests abundant protein but little machinery (cytoplasmic blue staining RNA) to produce additional protein.

The circulating neutrophil is a fully differentiated phagocyte capable of seeking out, ingesting, killing, and digesting invading microorganisms. Two forms of granules, specific granules and lysosomes, fill its cytoplasm. Specific granules contain substances, such as lactoferrin and cationic proteins, which are involved in bacterial killing. The lysosomes contain digestive enzymes, which act to dissolve organisms once killed.

While the neutrophil is a highly effective bacterial killing

machine, it is somewhat limited by its own high degree of sophistication and differentiation. Neutrophils are unable to divide, replenish their granule content, or regenerate surface membrane that is lost in internalization during phagocytosis of organisms. As a result, their lifespan is extremely short (hours to days).

Although neutrophils primarily function as phagocytes, it is noteworthy that these cells also function as secretory cells. Both when fusion of granules with phagocytic vacuoles occurs and when effete neutrophils break down, biologically active molecules are released into the microenvironment. Among these are prostaglandins, complement fragments, and biologically active amines. Clearly, by releasing these regulatory molecules into the environment, neutrophils (and, indeed, all phagocytes) function as moderators of the local and systemic inflammatory response.

Normal peripheral neutrophil counts in dogs and cats range between 3000/ $\mu$ l to 12,000/ $\mu$ l. In health, immature neutrophils (band cells) are only rarely observed (less than 300/ $\mu$ l when peripheral white cell counts are normal). Both increases (neutrophilia) and decreases (neutropenia) in neutrophil numbers are clinically significant, particularly in inflammatory diseases. Similarly, relative increases in band cells (termed a "left shift") are also extremely important clinically. To understand the interpretation of peripheral neutrophil numbers it is first important to understand neutrophil kinetics—the dynamics of neutrophil production, circulation, and utilization within the tissues.

Neutrophils are produced in the bone marrow, circulate transiently in the mainstream peripheral blood (the freely circulating pool), marginate on the blood vessel walls (the marginating pool), and migrate into the tissues. Within the marrow there are three pools of neutrophils and their precursors:

- 1) the proliferating pool, consisting of the dividing myeloblasts and promyelocytes, and early myelocytes,
- 2) the maturing pool, consisting of late nondividing myelocytes, metamyelocytes, and band cells, and
- 3) the storage pool, consisting of mature neutrophils.

In general, production of a neutrophil from a myeloblast takes approximately 5 days. The storage pool contains approximately a 5-day supply of mature neutrophils. In

other words, if white cell production were interrupted on day 1 and tissue demand, and therefore circulating half-life, were normal, it would be 5 days (day 6) before a reduction in neutrophil numbers would be recognized in peripheral counts. Neutrophils leaving the storage pool reside in the circulating pool (from which they are collected when blood is sampled) for only 6 to 8 hours before marginating and ultimately being drawn into the tissues chemotactically to perform their phagocytic function. For every neutrophil in the freely circulating pool, there is at least one marginating neutrophil.

When inflammatory foci develop in the tissues, production of chemotaxins causes increased release of neutrophils into the blood, shortened circulating half-life of neutrophils with increased margination, and increased egress of neutrophils into the tissues. Because of the large storage pool of marrow neutrophils, in most cases of inflammation, the movement of neutrophils into the blood is greater than the movement of neutrophils into the tissues; the net effect is peripheral neutrophilia. In a short time, the marrow storage pool of mature neutrophils is reduced to the point where increased numbers of band cells are drawn into the peripheral blood. Neutrophilia with a left shift (ie, a regenerative left shift) is the classic *acute* (active) inflammatory leukogram of dogs and cats.

Inflammatory foci release not only chemotaxins but also colony stimulating factors (CSF), which cause increased production of neutrophils. If the inflammation is not resolved quickly, marrow production of neutrophils will establish a new balance with tissue demand. Ultimately, the neutrophil count will return toward normal and the left shift tends to disappear. The classic *chronic* inflammatory leukogram features a normal or near normal neutrophil compartment.

In rare cases of severe acute inflammation, tissue demand is so great that egress of neutrophils from the blood may actually exceed influx of neutrophils from marrow. In these instances neutropenia with a left shift (ie, a degenerative left shift) develops rapidly and is an indication of overwhelming inflammation. In the dog and cat, this finding warrants a guarded prognosis.

## Eosinophils

The eosinophil is named for its distinctive red-orange (eosinophilic) cytoplasmic granules, which are variably sized and round in the dog (Fig. 2) and rod-shaped in the cat (Fig. 3). These granules contain hydrolytic enzymes and peroxidase (like the granules of neutrophils), as well as a core of basic proteins that give the granules their strong affinity for the eosin stain.

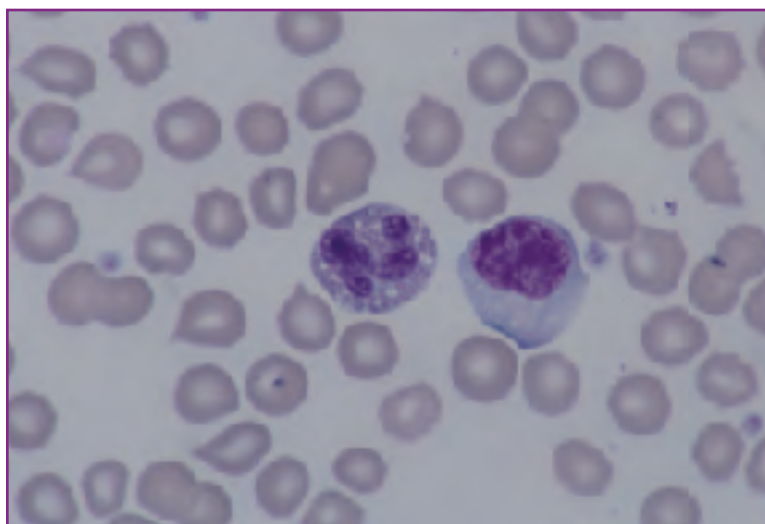


Fig. 2 Normal canine eosinophil (left), reactive lymphocyte (right).

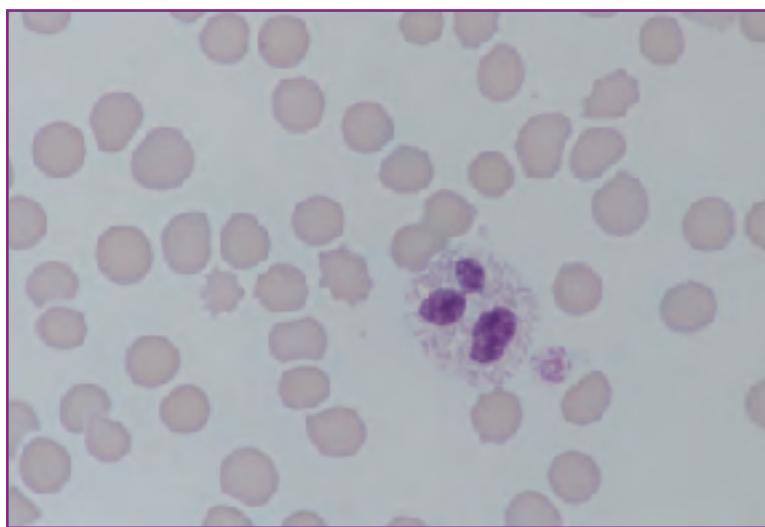


Fig. 3 Normal feline eosinophil.

Like neutrophils, eosinophils respond chemotactically to bacterial products and complement fragments. In addition, they are attracted preferentially to histamine and the eosinophilic chemotactic factor of anaphylaxis (ECF-A) released by mast cells, as well as to certain products released by activated lymphocytes. From a functional per-

spective, eosinophils are bactericidal *in vitro* but the extent to which they are bactericidal *in vivo* is uncertain. However, their role in modulating hypersensitivity reactions is clear; they elaborate antihistamines (amine oxidases) and prostaglandins that inhibit mast cell degranulation.

A second major function of the eosinophil is its role in the control of parasitic infections. Through antibody and/or complement mediated binding, eosinophils become fixed to the surface of helminth parasites and release their granule content into the microenvironment. Major basic proteins from the granules cause considerable damage to the parasite surface, which leads to parasite death.

Eosinophils have a much shorter circulating half-life than neutrophils (minutes to several hours as compared to 4 to 8 hours for neutrophils) so peripheral counts can be quite erratic from sample to sample. As a result, eosinophilia (an increase) is only significant when it is persistent over time. The most accurate interpretation of persistent eosinophilia is the presence of a systemic hypersensitivity reaction.

Parasitic infections are only associated with persistent eosinophilia if they have a systemic phase. For example, whipworm infections in dogs, which are confined to the intestinal tract, do not cause circulating eosinophilia. In contrast, heartworm infections, where circulating parasites are present, can cause marked eosinophilia. Other causes of persistent eosinophilias in dogs include systemic mastocytosis, fleabite dermatitis with systemic hypersensitivity, allergic gastroenteritis, allergic bronchitis, and atopy. In the cat, feline asthma, eosinophilic granuloma complex (systemic, not oral form), systemic mastocytosis, heartworm disease, and allergic gastroenteritis should all be considered. In the author's opinion, eosinopenia (a decrease) is less consistent and more difficult to interpret than eosinophilia.

## Basophils

Basophils (Figs. 4, 5, 6) are only occasionally observed on peripheral blood films. They are slightly larger than neutrophils with pale lavender cytoplasm and truly segmented nuclei. Basophils of dogs and cats often contain only a few distinctive deep blue to purple cytoplasmic granules; as a

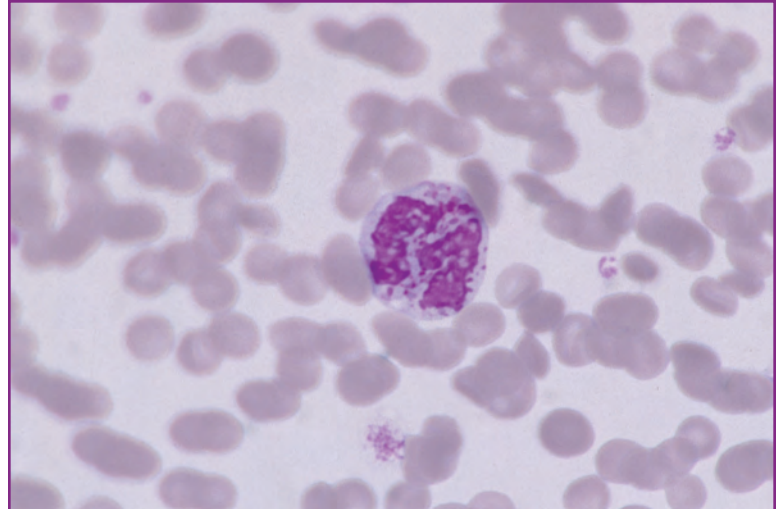


Fig. 4 Normal feline basophil.

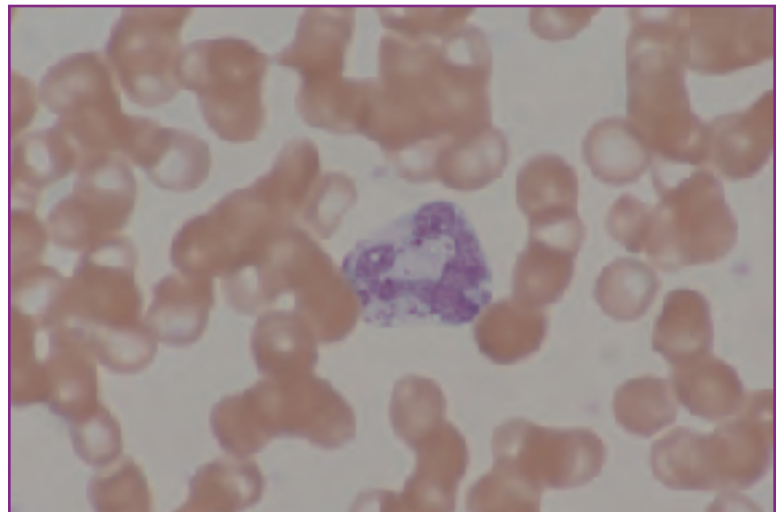


Fig. 5 Normal canine basophil.

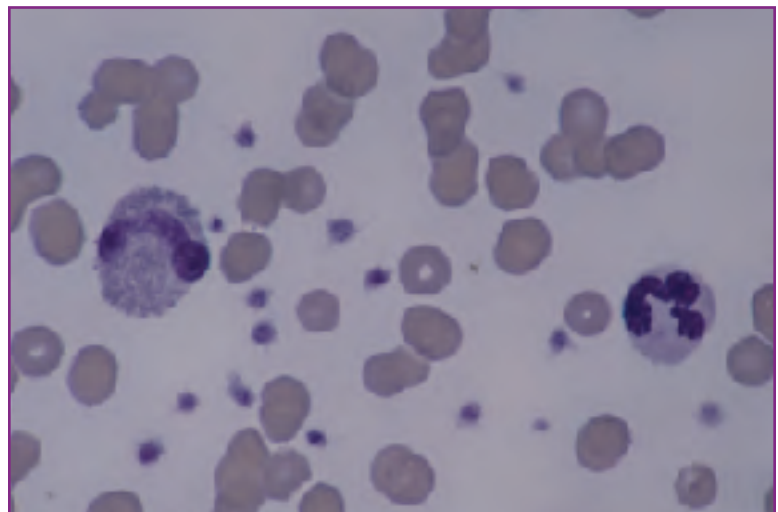


Fig. 6 Normal feline basophil (left), normal neutrophil (right).

result, they may be mistakenly identified as monocytes. Besides the truly segmented nucleus, which is useful in differentiating basophils from monocytes, the frequent observation of what appear to be small vacuoles in the nucleus—which are actually basophilic granules overlaying the nucleus—are quite characteristic of basophils.

Basophils are not phagocytic. Nevertheless, they play an essential role in the inflammatory process. Their cytoplasmic granules contain histamine and heparin. Histamine is one of the primary mediators of the acute inflammatory response, causing increased vascular permeability. Heparin is an anticoagulant that moderates the inflammatory microenvironment by inhibiting the formation of fibrin.

Basophilia is only rarely observed; when present, it almost always occurs in conjunction with eosinophilia.

## The Monocyte/Macrophage Continuum

The monocyte/macrophage continuum represents the second branch of the phagocytic system and is the primary link between the nonspecific and specific immune systems. This cell group was previously known as the reticuloendothelial system and includes not only the circulating monocytes but also the fixed macrophages of the liver, spleen, brain, and lymph nodes.

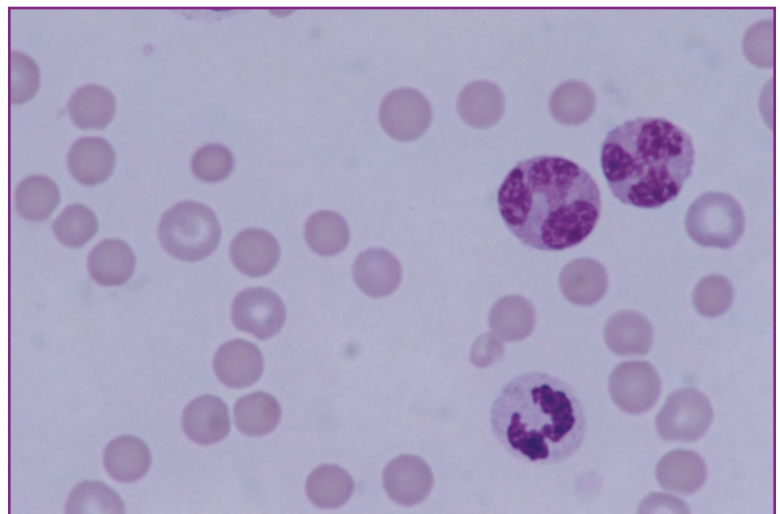
Monocytes are the precursors of all macrophages. They originate in the bone marrow, circulate in the peripheral blood, and settle out in the tissues where they differentiate further as needed. Differentiated cells of the monocyte/macrophage continuum include activated macrophages, epithelioid cells, and multi-nucleated inflammatory giant cells. In addition to their role as phagocytes, macrophages also perform the following functions:

- ❑ modify antigens in such a way that they can be recognized by immunocytes (antigen processing cells),
- ❑ release numerous inflammatory mediators that recruit neutrophils, other monocytes, and lymphocytes into inflammatory sites, and
- ❑ regulate iron stores.

The only cell of the monocyte/macrophage continuum normally seen in the peripheral blood is the monocyte. The immature nature of the monocyte is suggested by its morphology (*Fig. 7*). The nucleus is

irregularly shaped with a lacy to finely granular chromatin pattern suggestive of a preponderance of active **euchromatin**. Cytoplasm is abundant, often vacuolated, and gray to blue, which suggests a high content of cytoplasmic RNA but little protein. Monocytes seen on a peripheral blood slide are at approximately the same stage of development as the marrow myelocyte of the granulocyte series. In contrast to granulocytes, which are stored in marrow, monocytes are released immediately into circulation as they are produced. They have limited immediate phagocytic capability, but as mentioned above, possess significant potential to develop into fully armed effector cells once seeded in tissues.

Historically, peripheral monocytosis has been interpreted as indicative of chronic inflammation. Cells of the monocyte/macrophage continuum were regarded primarily as the clean-up cells of inflammation that were recruited into chronic lesions to remove debris after neutrophilic activity had localized the primary disease process. While the essential clean-up function of the monocyte/macrophage in chronic inflammation is undeniable, we now understand that these cells have a much greater role in the inflammatory process. Furthermore, since proliferating monocytes are released into and accumulate in the peripheral blood rather than being stored in the marrow, peripheral monocytosis can occur quite quickly (in as little as 12 hours). Consequently, the best clinical interpretation of monocytosis is simply that there is tissue necrosis and a demand for phagocytosis. Monocytosis can occur in either acute or chronic inflammation.



**Fig. 7** Two normal canine monocytes are at upper right. A normal canine neutrophil is at bottom for comparison.

## The Immunocytic System

The immunocytic or specific immune system is comprised of the circulating lymphocytes as well as the lymphocytes which are found in primary (bone marrow and thymus) and secondary (lymph node, spleen, Peyer's patches, and bronchus-associated lymphoid tissue) lymphoid organs.

Cells of the immunocytic system respond specifically to antigens by undergoing clonal expansion and differentiation into highly specialized effector cells and memory cells. Effector cells fall into two major classes:

- 1) T cell lymphocytes, which release a variety of biologically active molecules known as lymphokines and play a major role in cell-mediated immunity.
- 2) B cell lymphocytes, which produce immunoglobulins (antibodies) and constitute the humoral immune system.

T and B cell classes can be further subdivided into a number of subsets based upon cell surface markers.

T cell subsets include:

- helper cells, which are necessary for the full expression of the immune response,
- suppressor cells, which dampen or moderate the immune response, and
- null cells (essentially devoid of surface markers), which include natural killer (NK) cells and K cells.
  - NK cells release biologically active molecules capable of destroying other cells or microorganisms.
  - K cells participate in antibody-dependent cytotoxicity.

B cell subsets preferentially produce immunoglobulins belonging to a particular class:

- IgG
- IgD
- IgM
- IgE
- IgA

In addition to the obvious interplay among the lymphocyte classes and subclasses, lymphocytes also influence and are influenced by phagocytes. Among the **lymphokines** that T and B cells produce are numerous molecules that are chemotactic for both granulocytes and monocyte/macrophages. Some lymphocyte products may influence marrow production of phagocytes. Opsonization, as previously discussed, leads to enhanced phagocytosis.

Knowledge of the immunocytic system and its

complex functions has expanded dramatically in recent years. The study of lymphocytes and their various roles has evolved into the science of immunology, a review of which is beyond the scope of this chapter. Instead, the next section will focus on circulating lymphocytes and the interpretation of changes in circulating numbers and morphology.

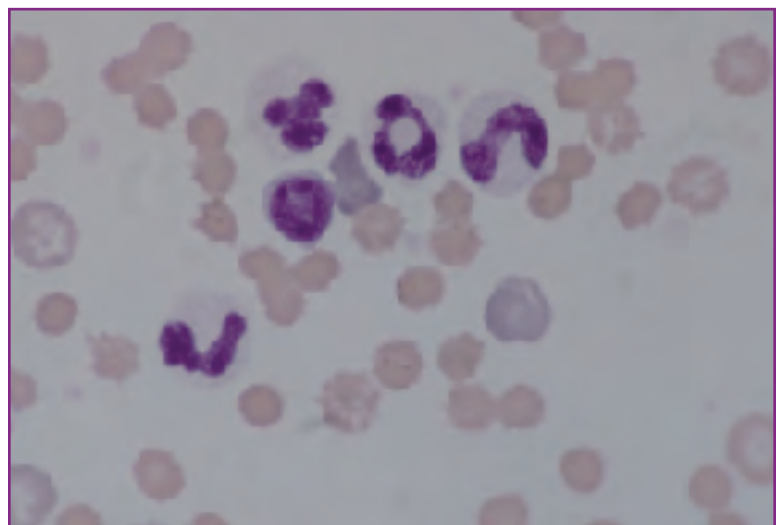### Normal lymphocyte structure and function

Circulating lymphocytes include representatives of T cell, B cell, and null cell classes. In most species, approximately 70% of circulating lymphocytes are T cells, 10% to 15% are B cells, and the remainder is comprised of null cells. Normal cells of the various classes cannot be differentiated morphologically using routine Romanowsky hematology stains.

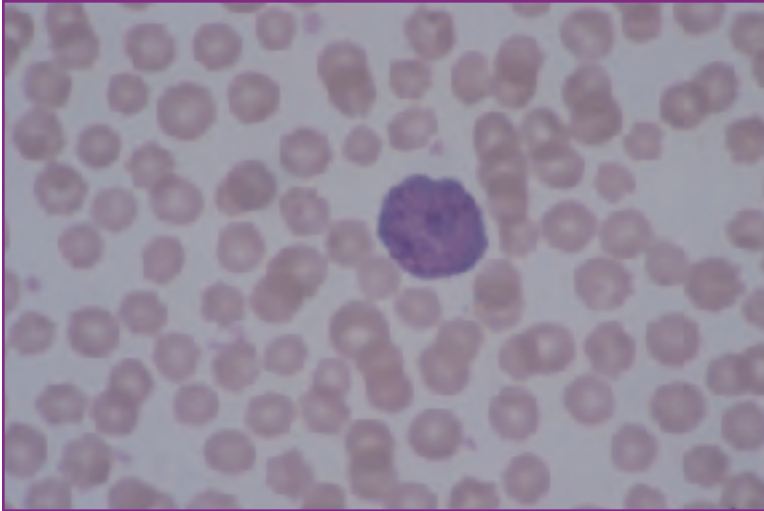
Normal circulating lymphocytes possess the following morphologic characteristics:

- round shape measuring 9.0  $\mu$  to 12.0  $\mu$  in diameter
- large, round, eccentric nuclei with densely stained, clumped chromatin patterns (*Fig. 8*)
- scant, pale blue cytoplasm, usually observable only on one side of the nucleus

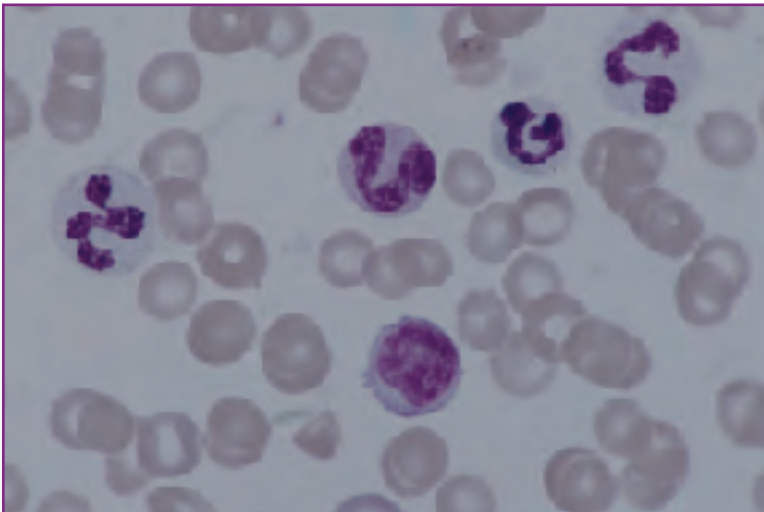
For the most part, circulating lymphocytes are long-lived "memory cells" which traverse back and forth between blood, lymph nodes, and lymph, monitoring for the presence of antigens to which they have been previously sensitized. When stimulated by such antigens, lymphocytes undergo blast transformation or activation. Activation is a normal process. However, increased relative or absolute numbers of activated lymphocytes (also known as reactive lymphocytes



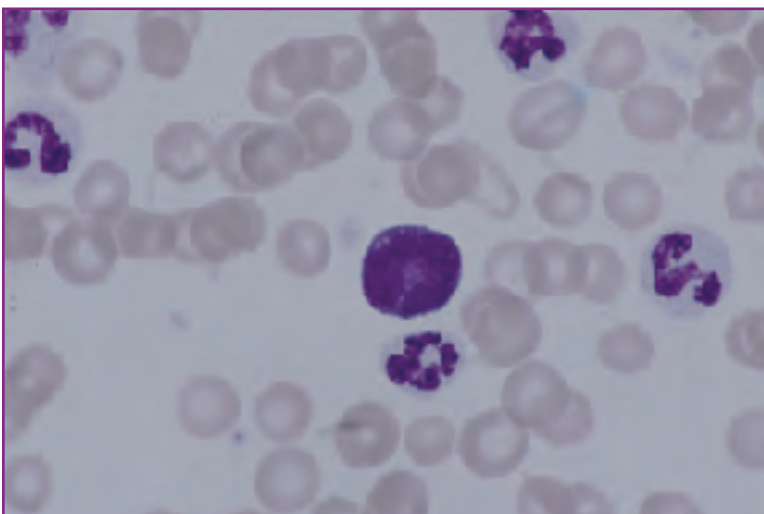
**Fig. 8** Normal small lymphocyte (round nucleus), three neutrophils, and normal band cell (right).



**Fig. 9** Blast-transformed (reactive, activated) lymphocyte.



**Fig. 10** Reactive lymphocyte (lower center), three neutrophils, and a monocyte (top center).



**Fig. 11** Reactive lymphocyte (center) and four neutrophils.

or immunocytes) indicates antigenic stimulation.

Morphologically, blast transformed lymphocytes are generally more heterogeneous than unstimulated lymphocytes (*Figs. 9 through 13*). They are larger than unstimulated lymphocytes with larger, more lacy nuclei and increased amounts of deep blue cytoplasm. Morphologically, activated B lymphocytes cannot be differentiated from activated T lymphocytes. However, fully differentiated B cells are plasma cells that are morphologically distinct (*Fig. 14*). Plasma cells have eccentric round nuclei with coarsely clumped nuclei, pale perinuclear clear zones (golgi zones), and abundant deep blue cytoplasm. Plasma cells are extremely rare on blood films except in cases of plasma cell tumor (multiple myeloma).

Normal lymphocyte counts are between 1000/ $\mu$ l and 5000/ $\mu$ l in dogs, and in cats the numbers may be as high as 7000/ $\mu$ l. Counts of between 1000/ $\mu$ l and 1500/ $\mu$ l are regarded as marginal lymphopenias. Both lymphopenia and lymphocytosis are relatively common clinical occurrences.

Lymphopenia in the range of 700/ $\mu$ l to 1500/ $\mu$ l is most likely a reflection of high levels of circulating glucocorticoids (ie, a stress reaction) where increased numbers of lymphocytes marginate along vessel walls or, in more chronic conditions, may be lysed. With more marked lymphopenia, processes which block the normal circulatory pattern of lymphocytes (blood to tissue to lymph and back to blood) must be considered. These include lymphosarcomas where lymphocytes leaving the blood become trapped in massively enlarged lymph nodes, or chylous effusions where lymphatic rupture leads to lymphocyte (and protein) sequestration in the body cavities.

Lymphocytosis occurs in cases of inflammation with antigenic stimulation, lymphocytic leukemia, and lymphosarcomas with leukemic events. In cases of leukemic lymphocytosis, circulating lymphocytes are almost always abnormal lymphoblasts. These cells are larger than normal with less intensely stained nuclei containing large nucleoli. Leukemias are also often accompanied by marked non-regenerative anemias. In cats, lymphocytosis can also occur physiologically,

where excitement (ie, epinephrine release) causes increased blood flow, washing marginated lymphocytes into the circulating mainstream where they can be readily sampled and counted. Physiologic lymphocytosis in cats, with lymphocytes counts as high as 20,000/ $\mu$ l, has been observed. Lymphocytes, in these cases, are morphologically normal and there is no anemia.

## Abnormal Leukocyte Morphology

### Neutrophil toxicity

Toxicity in neutrophils is seen when circulating toxins interfere with the development and differentiation of neutrophil precursors in the bone marrow. In dogs and cats, toxicity is most commonly caused by circulating bacterial toxins. However, tissue necrosis, a variety of drugs, and numerous non-specific toxins such as lead are all capable of interfering with neutrophil development. Toxic neutrophils in the blood are best interpreted as indicating the presence of unspecified systemic toxemia.

Because toxicity indicates maturation arrest, the stage of development affected may be important in assessing prognosis or gauging response to therapy. In cases where both mature neutrophils and band cells are equally affected, no such interpretation is possible. However, in cases where mature neutrophils are toxic but bands are normal, morphology would suggest that the systemic toxemia is resolving. In contrast, in cases where bands are toxic but mature neutrophils are normal, morphology suggests a worsening condition.

Morphologically, toxic neutrophils exhibit a variety of alterations that reflect either cytoplasmic or nuclear developmental arrests or both (*Fig. 15 through 18*). The most common form of toxicity in dog and cat neutrophils is foamy basophilia of the cytoplasm. This is a reflection of retention of cytoplasmic RNA and failure of the affected cells to form their normal complement of protein and cytoplasmic granules. Döhle bodies, a relatively minor sign of toxicity in cat neutrophils but a sign of marked toxicity in dog neutrophils, are simply intracytoplasmic precipitates of RNA and appear as blue basophilic cytoplasmic inclusions. Some toxic

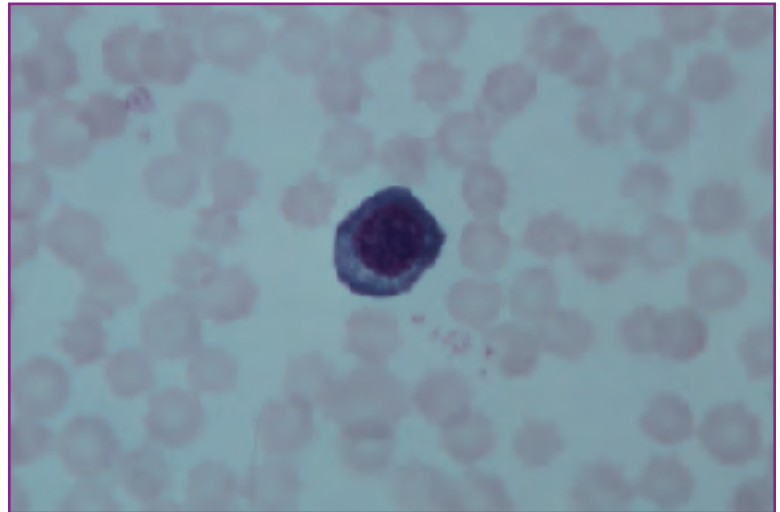


Fig. 12 Reactive lymphocyte

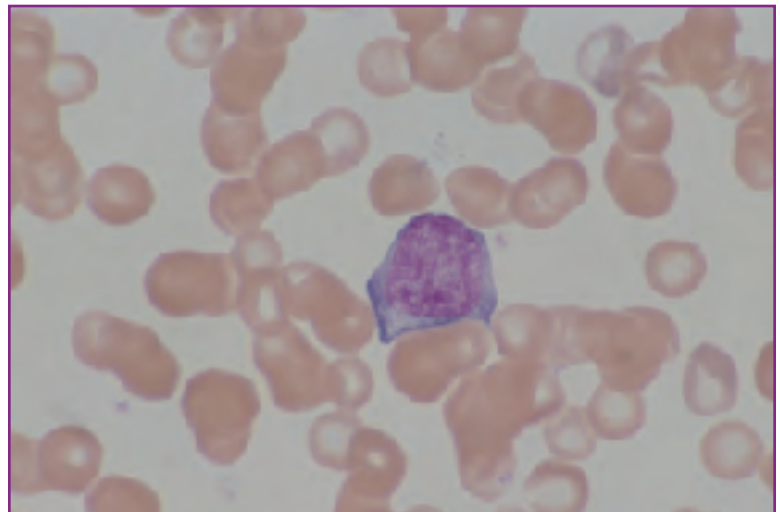


Fig. 13 Reactive lymphocyte

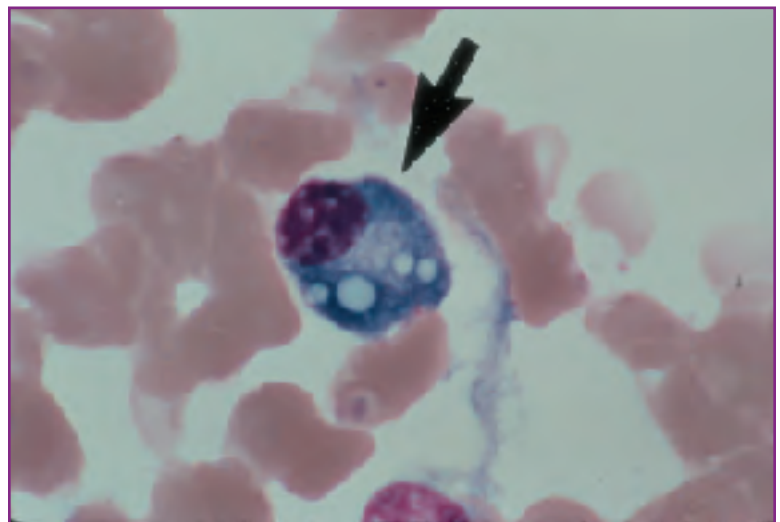
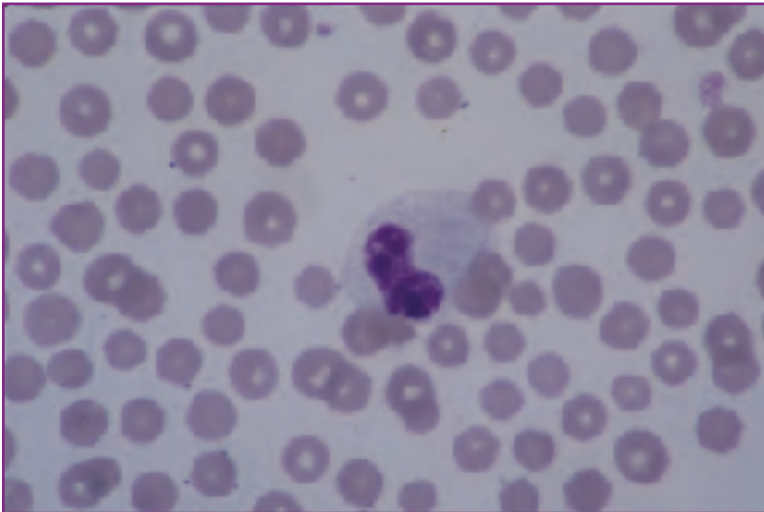
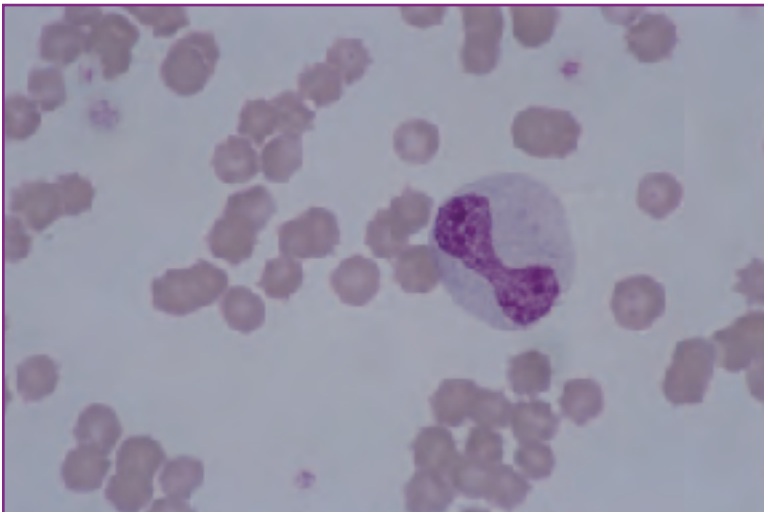


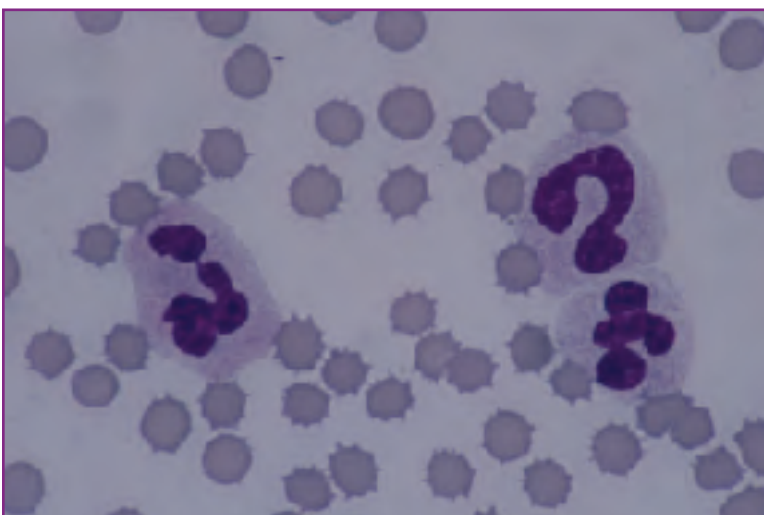Fig. 14 Fully differentiated plasma cell.



**Fig. 15** Toxic band cell with foamy, basophilic cytoplasm



**Fig. 16** Giant toxic band with foamy, basophilic cytoplasm and giant, irregular nucleus.



**Fig. 17** Two toxic neutrophils and a toxic band. Note the unusual nuclear shape.

neutrophils are extremely large; this is a reflection of nuclear maturation arrest characterized by failure of developing cells to divide properly. Bizarre nuclear shapes and even multiple nuclei also are indicative of nuclear maturation arrests.

### **Atypical lymphocytes**

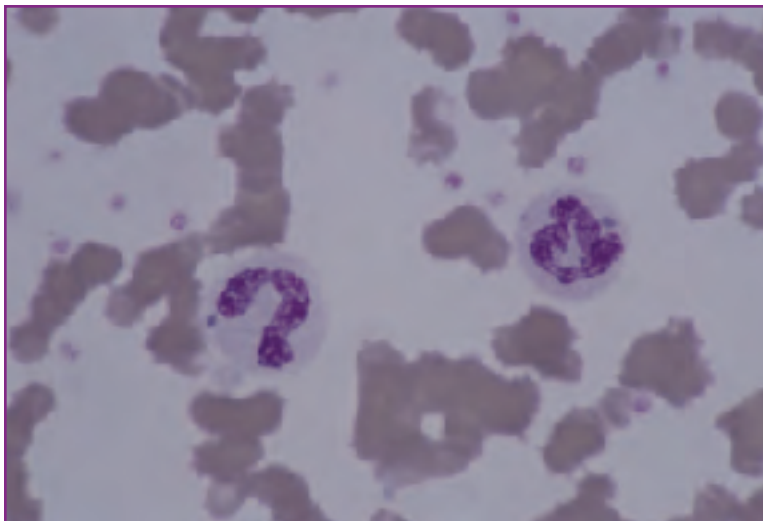
“Atypical lymphocyte” is a term used to describe a heterogeneous group of circulating cells of the lymphoid series with a variety of either nuclear or cytoplasmic abnormalities or both. Atypical lymphocytes are morphologically distinct from reactive lymphocytes (immunocytes, activated lymphocytes), which are normal antigen-stimulated lymphocytes.

Nuclear and cytoplasmic features determine atypical classification. Lymphocytes containing

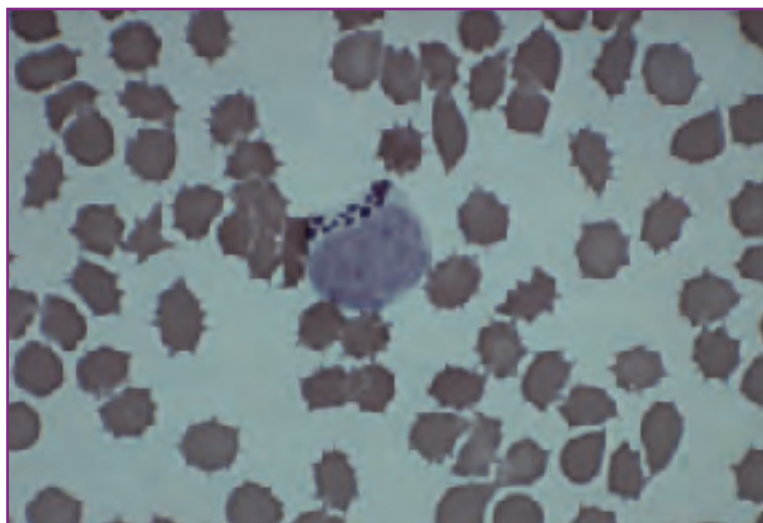


large, angular nucleoli are sometimes classified as atypical, although these cells may simply be reactive. Lymphocytes with clefted nuclei (Reider-form nuclei) are considered atypical. The presence of large, azurophilic cytoplasmic granules in lymphocytes is also regarded as atypical (*Fig. 19*).

The significance of observing atypical lymphocytes on blood films is uncertain. Historically, atypical lymphocytes were thought to indicate viral infections. We now know that this relationship is obscure; animals ill from a variety of causes may have increased numbers of circulating typical lymphocytes. The presence of atypical lymphocytes in the blood should be noted, but no particular interpretation should be made on the basis of this finding alone.



**Fig. 18** Two toxic neutrophils with Döhle bodies.



**Fig. 19** Atypical lymphocyte

# Chapter 2: Erythrocytes in Health and Disease

## Overview

The primary functions of the erythron, or red blood cell (RBC), are as follows:

- to accumulate oxygen at the alveolar surface of the lung,
- to transport and release it to all the cells of the body,
- to replace the released oxygen with the waste gas, carbon dioxide, and
- to transport the carbon dioxide back to the alveolus where it can be removed from the body via expiration.

To accomplish these functions, mammalian red cells have evolved into highly sophisticated yet simple transport vehicles comprised of hemoglobin (a soluble transport protein) sealed in a protective cell membrane. This architecture gives the red cells great flexibility, allowing them to circulate through the most tortuous of vascular spaces. The metabolic pathways of red cells, glycolysis and the hexose monophosphate shunt, serve primarily to maintain the integrity of the cell membrane and the hemoglobin molecule.

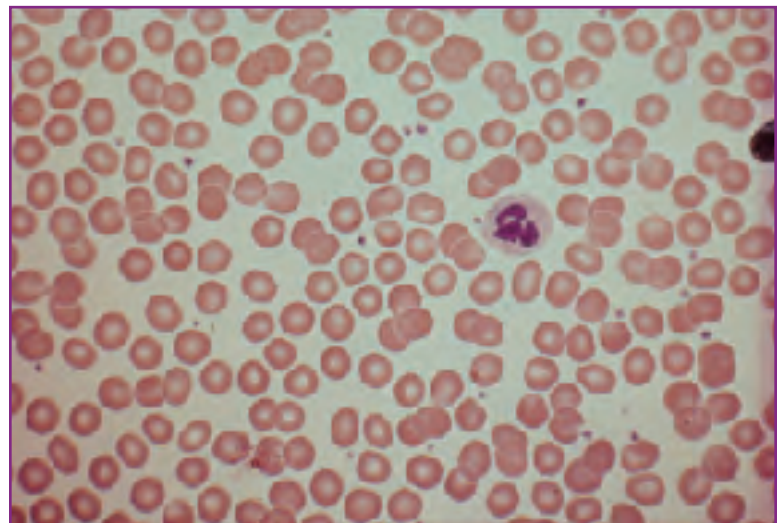
In health, circulating red cell mass, and therefore oxygen carrying capacity, is kept remarkably constant from day to day and year to year. For each species, red cell lifespan is finite and preprogrammed. The rate of production of new red cells, as regulated by circulating **erythropoietin** levels, is inversely related to red cell lifespan. In dogs, circulating red cell lifespan is approximately 100 days; therefore approximately 1% of circulating red cells die and must be replaced on a daily basis. Cat red cells have a shorter average lifespan (approximately 80 days); therefore, a somewhat higher rate of red cell production rate is required to maintain normal circulating red cell mass.

Red cell morphology is also unique for each species. Dog red cells measure 6.5  $\mu$  to 7.0  $\mu$  in diameter, have prominent areas of central pallor, are uniformly round, and show little variability in size and shape from cell to cell (*Fig. 1*). Mean cell

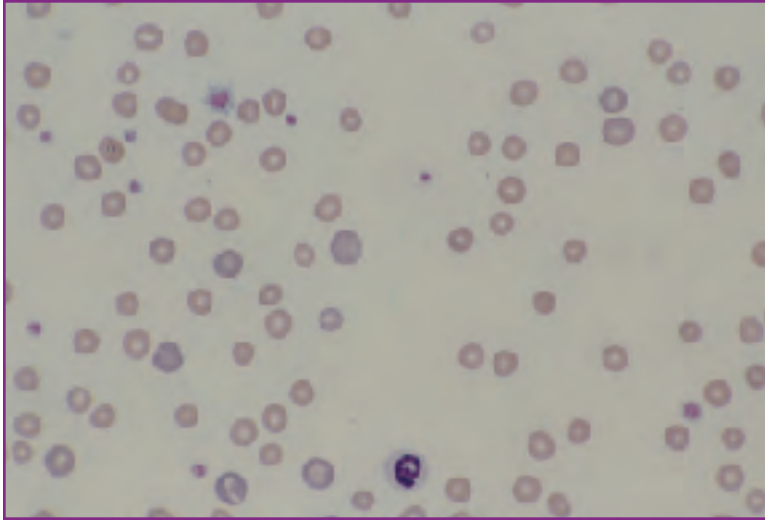
Red Cell Morphology	
Canine	Feline
6.5 $\mu$ to 7.0 $\mu$ in diameter, uniformly round	5.0 $\mu$ to 6.0 $\mu$ in diameter
Prominent areas of central pallor	Minimal central pallor
MCV = 60 fl to 75 fl	MCV = 40 fl to 55 fl
Moderate rouleau formation	Marked rouleau formation

volume (MCV) is 60 femtoliters (fl) to 75 fl. Approximately 1% of the red cells are larger than normal and stain with a bluish cast on Romanowsky-stained films; these are immature red cells known as **polychromatophils** (*Fig. 2*). Their bluish cast is a reflection of their higher content of cytoplasmic RNA and reduced content of hemoglobin. Normal canine red cells show moderate tendency to form stacks or rows (rouleau formation).

Feline red cells are smaller than those of dogs, measuring 5.0  $\mu$  to 6.0  $\mu$  in diameter with MCVs of 40 fl to 55 fl. Central pallor is minimal. The proportion of polychro-



**Fig. 1** Normal canine blood film. Scanning magnification. RBCs are uniform in size, shape, and color and feature prominent central pallor.



**Fig. 2** Canine blood film with increased polychromasia. Scanning magnification. Polychromatophils are bluish and generally larger than mature cells.

matophils is higher in cats than in dogs (up to 2% in cats). This is a reflection of shorter feline red cell lifespan and therefore greater marrow production and release of reticulocytes. There is marked rouleau formation in cats.

Disorders of the erythron are essentially disorders of red cell mass (ie, total red cell count, hematocrit, and hemoglobin). Red cell mass can be increased (**polycythemia**) or decreased (anemia). The following paragraphs detail the diagnostic approach to the evaluation of these two broad categories of disease.

## Polycythemia

Polycythemia is diagnosed when measures of red cell mass are increased. Polycythemia can be relative or absolute.

Relative polycythemia is the result of hemoconcentration (dehydration) and is by far the most common form of polycythemia in dogs and cats. Elevated total protein as well as an elevation in total red cell count and hematocrit characterize the condition, which is reversed by returning blood volume to normal.

Absolute polycythemia is either secondary or primary. Secondary absolute polycythemia occurs as a result of increased production of erythropoietin, either appropriately as a compensatory response to diseases where there is reduced oxygenation of the tissues (eg, heart disease or pneumonia) or inappropriately in rare cases of renal disease or renal neoplasia. There are no peripheral

blood morphologic abnormalities in secondary polycythemia. Primary absolute polycythemia is **polycythemia vera**, a rare myeloproliferative disorder. Polycythemia vera is characterized by expanded red cell production in the marrow but no morphologic abnormalities in the peripheral blood. The condition is diagnosed by ruling out secondary causes of polycythemia and demonstrating normal blood gas values in the face of elevated red cell mass measures.

## Anemia

Anemia is one of the most common syndromes in all of veterinary medicine and is associated with a wide range of specific diseases. Anemias fall into two broad categories: regenerative and non-regenerative.

Regenerative anemia is characterized by appropriate bone marrow response with release of increased numbers of normal immature red cells into the blood. Regenerative anemia is either the result of blood loss (hemorrhage) or hemolysis.

In non-regenerative anemia, marrow response is ineffec-

## Anemia

### I. Regenerative Anemias:

*Blood Loss/Hemorrhagic Anemia*

*Hemolytic Anemias*

Immune-mediated hemolytic anemias

Heinz body hemolytic anemia

Infectious hemolytic anemias

*Hemobartonellosis*

*Babesiosis*

Hereditary hemolytic anemia

Microangiopathic hemolytic anemia

Metabolic anemia with spiculated red cells

### II. Non-regenerative Anemias:

*Maturation Defect Anemias*

Nuclear maturation defect

Cytoplasmic maturation defect

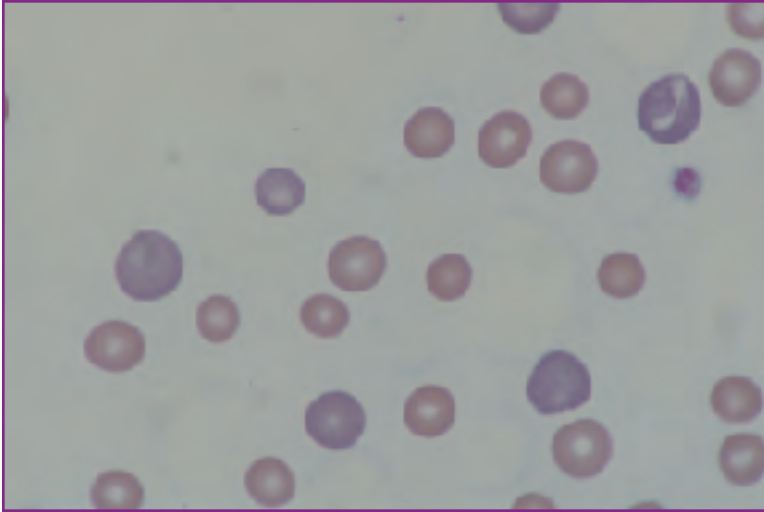
*Hypoproliferative Anemias*

Due to inflammatory disease

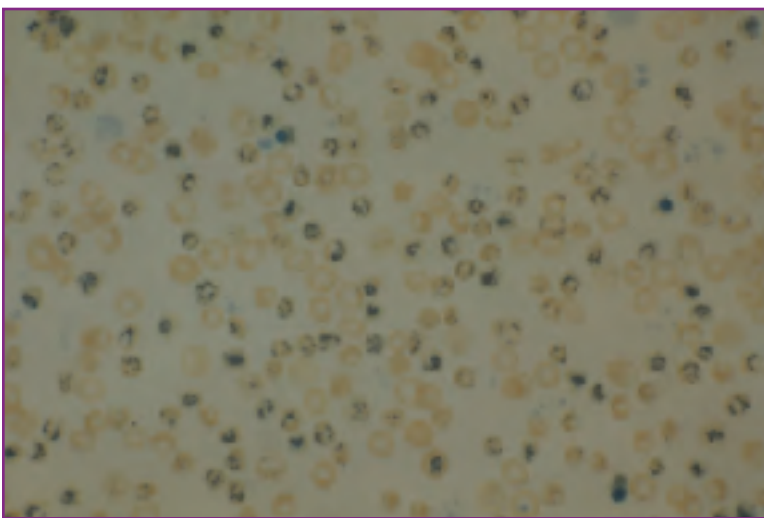
Due to reduced erythropoietin

Myelophthisic anemia

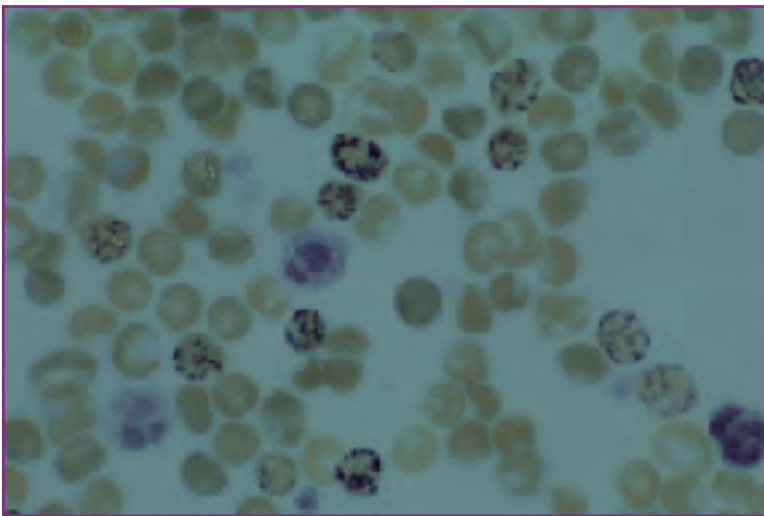
Due to marrow toxicity



**Fig. 3** Higher magnification of Fig. 2. This represents a regenerative anemia with marked polychromasia. Note the marked separation of RBCs.



**Fig. 4** Low magnification of a new methylene blue-stained blood film. Reticulocytes stand out due to blue-stained reticulum visible at this magnification. This represents a highly regenerative anemia.



**Fig. 5** High magnification of Fig. 4. Reticulocytes with precipitated blue reticulum are obvious. In dogs, all would be counted; in cats, only those with abundant precipitate (aggregate reticulocytes) would be counted. Several leukocytes are also present.

tive or inadequate and immature red cells are not released into the blood in sufficient numbers. Causes of non-regenerative anemia are several and often require bone marrow examination for differentiation.

The first step in classifying an anemia as regenerative or non-regenerative is evaluation of the peripheral blood film (Figs. 2, 3). Increased numbers of polychromatophils on the film suggests regeneration. Because polychromatophils are larger than mature cells and have less hemoglobin, MCV may be increased and mean cell hemoglobin concentration (MCHC) may be reduced.

If significant polychromasia is present, determining reticulocyte numbers can more accurately assess regeneration. This is done by mixing a small amount of EDTA blood with an equal volume of a vital stain such as new methylene blue. The mixture is allowed to incubate at room temperature for thirty minutes and then air-dried blood films are made. The cytoplasmic RNA in immature red cells is precipitated by the new methylene blue as a dark blue reticulum. Cells containing this precipitate are identified as reticulocytes (Figs. 4, 5).

In dogs, all cells with reticulum are counted when determining a reticulocyte count. In cats, three types of reticulocytes may be identified and are distinguished by the amount of reticulum present:

- 1) punctate reticulocytes, which have only focal precipitates,
- 2) aggregate reticulocytes, which contain an extensive network of reticulum, and
- 3) intermediate reticulocytes, which have intermediate amounts of precipitate.

Only aggregate reticulocytes are counted in cats.

Absolute reticulocyte counts are used to judge whether or not regeneration is present. The number of appropriate reticulocytes per 1000 total red cells is noted and converted to a percentage. The

### Absolute Reticulocyte Count Formula

- # reticulocytes/1000 RBC
- convert to %
- x total RBC count

percentage can then be multiplied by the total red cell count to obtain an absolute reticulocyte count. An absolute reticulocyte count of greater than 80,000/ $\mu$ l is indicative of regeneration in both dogs and cats.

## Regenerative Anemias

### Blood loss anemia

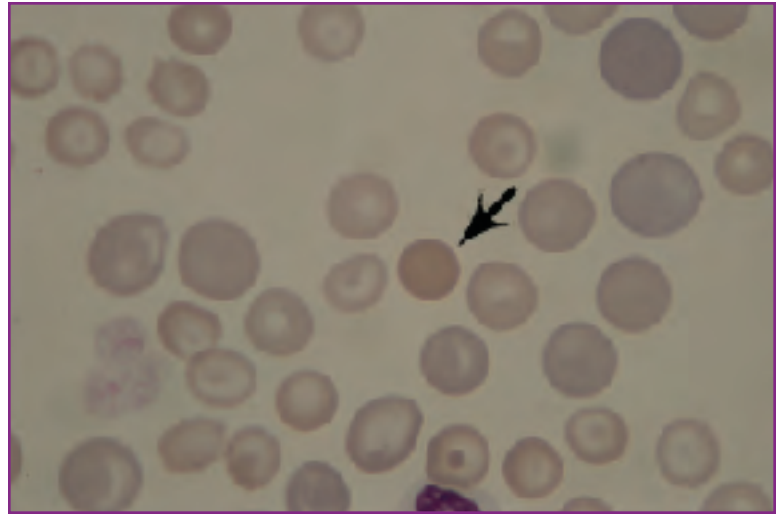
In hemorrhagic anemias, circulating red cell lifespan is normal but red cells are lost from the body due to external bleeding. A history of bleeding or physical findings consistent with blood loss generally makes the diagnosis fairly obvious in these cases. The degree of regeneration in blood loss anemia is moderate (no more than two to three times normal) and is a function of the iron depletion that accompanies red cell loss. The availability of iron for incorporation into hemoglobin directly influences the rate of red cell production and, therefore, the degree of peripheral reticulocytosis.

Cases of severe or chronic blood loss may actually be non-regenerative because of the lack of iron. Iron deficiency anemia, the end stage of blood loss anemia, is described under Cytoplasmic Maturation Defects in the section titled *Non-regenerative Anemias* of this chapter.

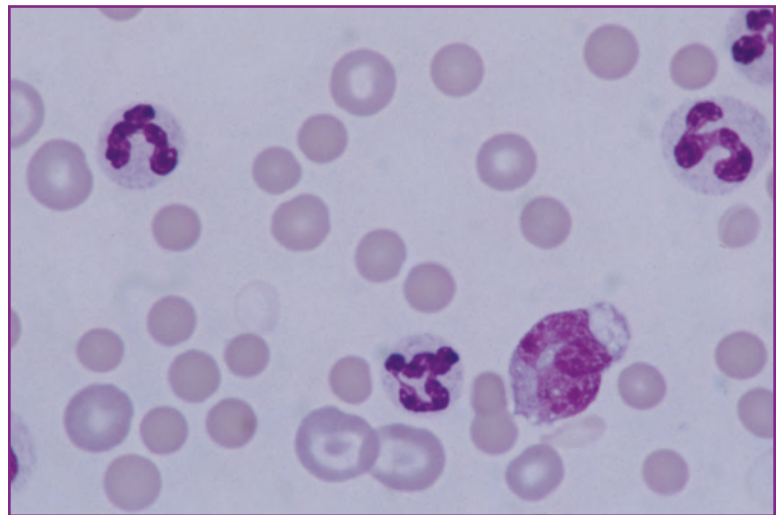
### Hemolytic anemias

The essential feature of hemolytic anemias is shortened red cell lifespan. Hemolysis can occur intravascularly as the cells circulate or extravascularly within macrophages of the liver and spleen. In either case, iron is conserved in the body and is readily available for reincorporation into hemoglobin. As a result, hemolytic anemias are often more highly regenerative than blood loss anemias with reticulocyte counts sometimes exceeding three times normal.

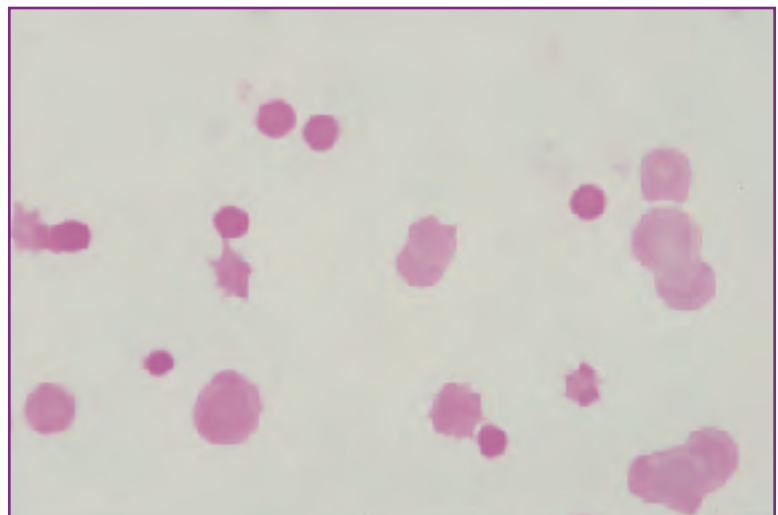
In many forms of hemolytic anemia, there are specific morphologic indicators of the underlying etiology. Included among these are immune-mediated hemolytic anemias, **Heinz body** hemolytic anemia, infectious hemolytic anemias, hereditary hemolytic anemia, microangiopathic hemolytic anemia, and metabolic anemia with spiculated red cells.



**Fig. 6** Canine immune-mediated hemolytic anemia. The anemia is highly regenerative with marked polychromasia. A spherocyte (arrow).



**Fig. 7** A second case of canine immune-mediated hemolytic anemia with numerous spherocytes.



**Fig. 8** Feline immune-mediated hemolytic anemia. Spherocytes are numerous but less obvious due to the lack of central pallor in the normal RBCs.

### ***Immune-mediated hemolytic anemia***

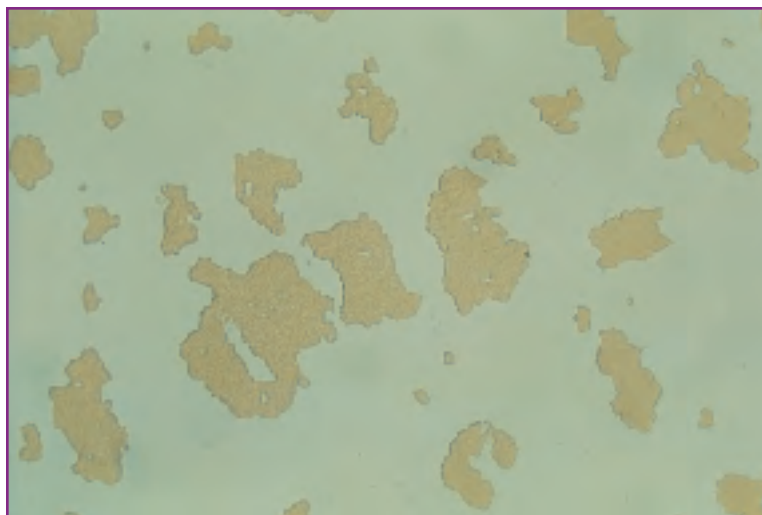Immune-mediated hemolysis occurs when antigen-antibody complexes form on the surface of circulating red cells. The antibody may be directed against an antigen in the red cell membrane itself (autoimmune hemolytic anemia) or against a foreign antibody (eg, drug, infectious agent) carried on or bound to the red cell surface. Regardless of the site of antibody activity, the antigen-antibody complex activates complement, which leads either to intravascular lysis or removal of red cells by macrophages in the spleen and liver.

Immune-mediated hemolytic anemias are typical regenerative anemias, characterized by marked polychromasia and anisocytosis (variable cell size – *Fig. 6*). The presence of significant numbers of spherocytes is a specific morphologic indicator of immune-mediated hemolysis, although they may occur in low numbers in other conditions. Spherocytes are round, smaller than normal, intensely stained, and lack central pallor (*Fig. 7*). They are more difficult to recognize in cats than in dogs because feline red cells are normally fairly small and lack central pallor (*Fig. 8*).

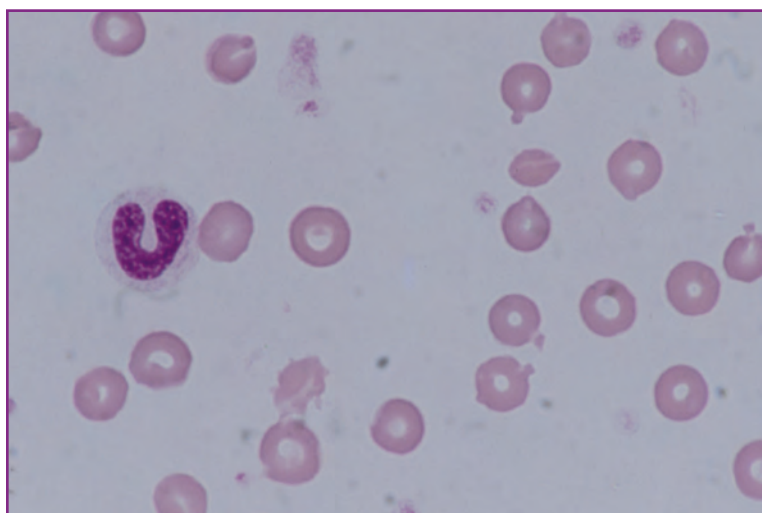Another feature of some immune-mediated hemolytic anemias is **autoagglutination** (three-dimensional clumping of RBCs). Autoagglutination, the result of true cross-linking of red cells by antibodies, confirms the diagnosis of immune-mediated disease.

Autoagglutination must be differentiated from rouleau formation. This is done by placing a drop of well-mixed EDTA blood on a slide, adding an equal or slightly larger volume of isotonic saline, coverslipping the mixture, and evaluating the finished wet preparation under the microscope (*Fig. 9*). If clumping persists, autoagglutination is present. Rouleau, the result of attraction between red cells on the basis of surface charge, will be dissipated by the dilutional effect of the saline.

In the absence of autoagglutination, immune-mediated hemolysis can be confirmed with a direct antiglobulin test (DAT). The DAT is performed by mixing well-washed suspect red cells with anti-complement and serial dilutions of commercially available species-specific anti-IgG. Microscopic evidence of agglutination of red cells confirms the diagnosis.



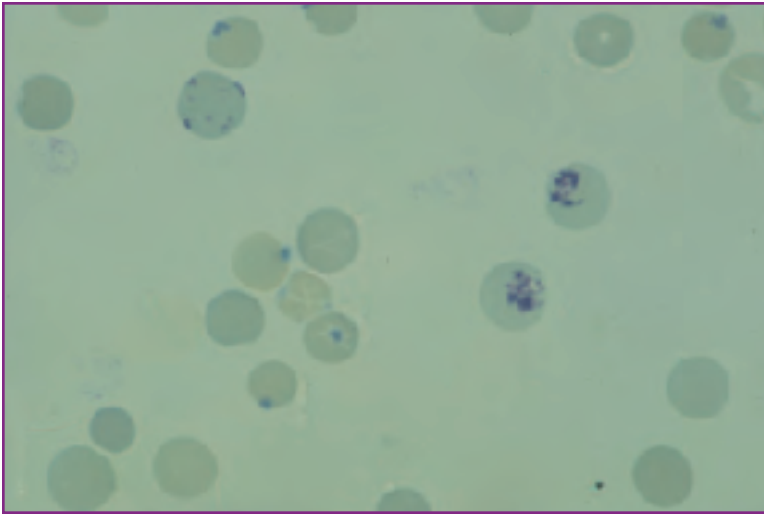
**Fig. 9** Saline-diluted wet preparation demonstrating autoagglutination.



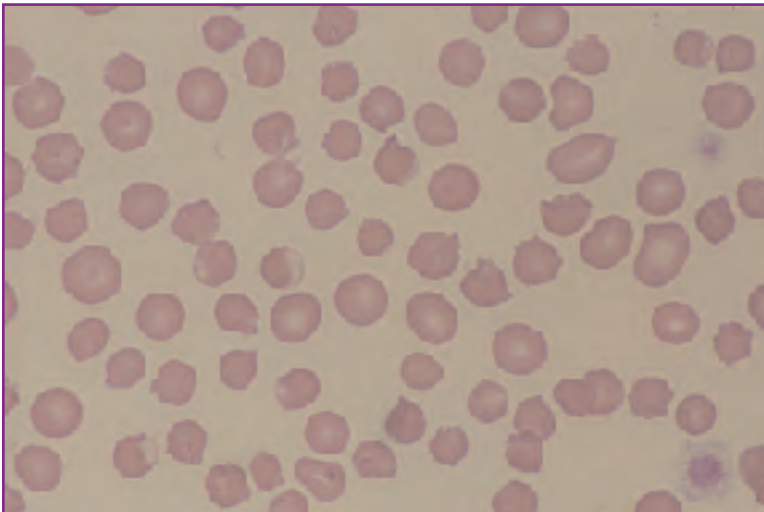
**Fig. 10** Heinz body hemolytic anemia in the dog. Several red cells with nose-like projections (Heinz bodies) are present. The leukocyte at left is a band cell.

### ***Heinz body hemolytic anemia***

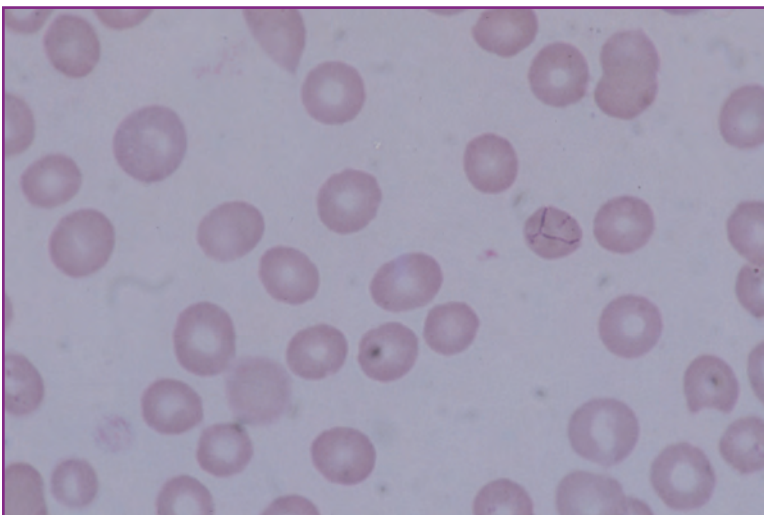
Heinz bodies are masses of precipitated hemoglobin formed when increased levels of circulating oxidants overwhelm red cell biochemical defense mechanisms and damage globin. The presence of Heinz bodies interferes with red cell flexibility, reducing red cell lifespan. Cells containing Heinz bodies are either lysed as they squeeze through tortuous vascular spaces (intravascular hemolysis) or are trapped in the spleen and are removed by macrophages (extravascular hemolysis). Because Heinz bodies often become attached to the inner red cell membrane, they may be recognized on peripheral blood films as nipple-like projections from the red cell surface (*Fig. 10*). They have the same staining properties as normal hemoglobin with Romanowsky stains, but stain a royal blue with new methylene blue (*Fig. 11*).



**Fig. 11** Canine Heinz body hemolytic anemia, new methylene blue stain. Several cells with Heinz bodies (upper left). Two reticulocytes with aggregated reticulum (right center).



**Fig. 12** Feline hyperthyroidism. Numerous cells have obvious Heinz bodies projecting from their surfaces, but anemia is not present.



**Fig. 13** Canine hemobartonellosis. The cell at lower right center has several chains of basophilic organisms on its surface.

There are species differences in susceptibility to Heinz body formation and Heinz body hemolytic anemia. Dogs are quite resistant to Heinz body formation; the demonstration of Heinz bodies on blood films is enough to confirm the diagnosis of Heinz body hemolytic anemia in dogs.

In contrast, the hemoglobin of cats is easily oxidized and Heinz body formation is quite common. In fact, even in health, up to 10% of normal feline red cells contain Heinz bodies. In metabolic disorders such as hyperthyroidism, diabetes mellitus, or liver disease, the number of red cells with Heinz bodies can increase dramatically (up to 80% or higher) without the presence of hemolysis or anemia (Fig. 12). In cats, therefore, the diagnosis of Heinz body hemolytic anemia requires not only the presence of Heinz bodies but also the presence of a highly regenerative anemia.

In cats, most cases of Heinz body hemolytic anemia are caused by the use of oxidant drugs, such as aspirin. In contrast, drug-induced Heinz body hemolytic anemia in dogs is relatively rare. The most common cause of spontaneous Heinz body hemolysis in dogs is ingestion of large amounts of raw onions, which contain the oxidant, N-propyl disulfide.

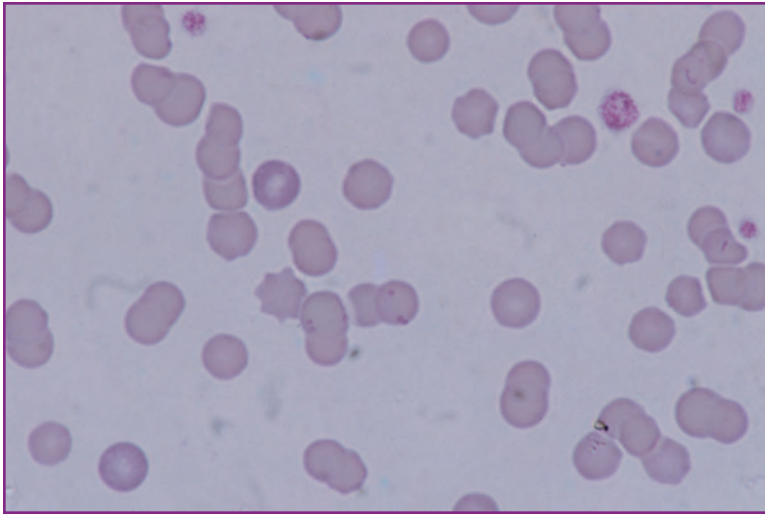
### *Infectious hemolytic anemias*

Infectious hemolytic anemias include leptospirosis, hemobartonellosis, and babesiosis. There are no specific morphologic indicators of bacterial-induced hemolysis. In contrast, in both hemobartonellosis and babesiosis, etiologic agents are seen on peripheral blood films.

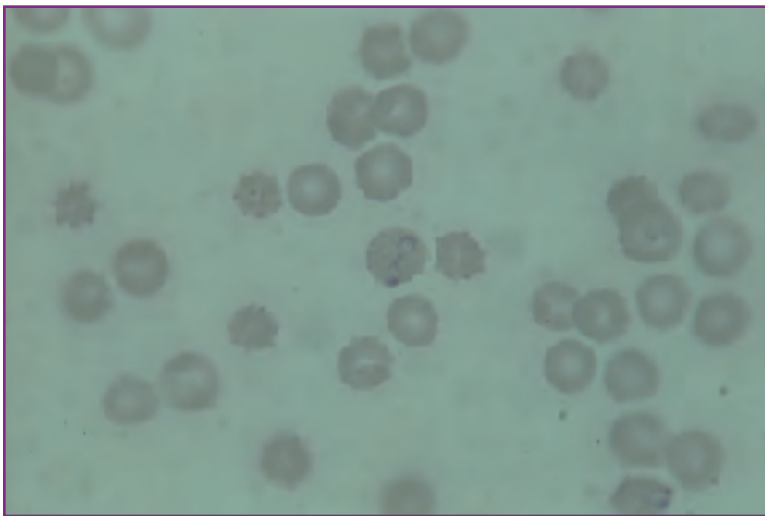
### *Hemobartonellosis*

Hemobartonellosis occurs in both dogs and cats. In dogs, the disease is uncommon and occurs almost exclusively in splenectomized or immunosuppressed patients. Clinically, canine hemobartonellosis presents as a typical hemolytic anemia with marked polychromasia and anisocytosis on routine peripheral blood films. *Hemobartonella canis* organisms are seen as chains of small (0.5  $\mu$ ) basophilic bodies on the red cell surface (Fig. 13).

In cats, the disease may be primary or may occur secondarily to primary immunosuppressive



**Fig. 14** Feline hemobartonellosis. Several cells near the center have multiple basophilic *Hemobartonella felis* organisms on their surfaces.



**Fig. 15** Canine babesiosis. The cell (center) has two teardrop-shaped organisms. A red cell (lower right) with a single organism.

disorders, such as feline infectious peritonitis (FIP) or feline leukemia virus (FeLV) infections.

Primary feline hemobartonellosis is a typical hemolytic anemia with all the attendant signs of marked red cell regeneration (Fig. 14). Agglutination also may be present, suggesting an immune component to the disease. As in dogs, *Hemobartonella* organisms (*Hemobartonella felis*) are seen on the red cell surface. They are generally slightly larger than *H. canis*, and may be present as chains, individual basophilic bodies, or ring forms. Splenomegaly is a common clinical finding in cats with hemobartonellosis. Primary feline hemobartonellosis responds well to tetracyclines with good prognosis for recovery.

Secondary feline hemobartonellosis is far more common and the prognosis is poor. The anemia is generally non-regenerative because the marrow is suppressed and cannot

respond. The diagnosis is based on the presence of large numbers of organisms on blood films. These are removed with tetracycline therapy, but this does not resolve the underlying disease. Because of the close association of hemobartonellosis with immunosuppressive viruses, all cases of feline hemobartonellosis should be tested for feline immunodeficiency virus (FIV), FIP, and FeLV.

### ***Babesiosis***

Babesiosis is a relatively uncommon tick-borne hemolytic anemia of dogs. The causative organism, *Babesia canis*, is a teardrop-shaped protozoan measuring 2.0  $\mu$  to 2.5  $\mu$  in length.

*B. canis* organisms are found in varying numbers within red cells on blood films from affected animals (Fig. 15). Anemia is often rapid in onset and can be quite severe and highly regenerative. There is often an immune-mediated hemolytic component to the disease; spherocytes may be observed in significant numbers. There have been cases reported with low numbers of organisms initially misdiagnosed as immune-mediated hemolytic anemia. Inappropriate treatment of these patients with steroids results in reduced removal of organisms by splenic macrophages and a concomitant buildup of organisms in the blood. Upon re-evaluation, the organisms are readily apparent, and a correct diagnosis can be made.

### ***Hereditary hemolytic anemia***

Two forms of hereditary hemolytic anemia associated with glycolytic enzyme deficiencies have been described in dogs: pyruvate kinase deficiency and phosphofructokinase deficiency.

Pyruvate kinase deficiency is described in Basenjis and Beagles, and is characterized as a chronic hemolytic anemia with extremely high reticulocyte counts. Shortened red cell lifespan is a reflection of decreased ATP production and reduced stability of the red cell membrane. Pyruvate kinase deficiency is generally diagnosed at 3 to 6 months of age when the anemia is moderately severe. Hematocrit values continue to decline slowly thereafter as the compensatory capacity of the marrow deteriorates. The condition may terminate in marrow exhaustion, myelofibrosis, or both.

Phosphofructokinase deficiency has been described in



two Springer Spaniels. The condition is less severe than pyruvate kinase deficiency, and is characterized by moderate chronic hemolysis with superimposed episodes of more severe hemolysis associated with exercise and overheating.

### ***Microangiopathic hemolytic anemia***

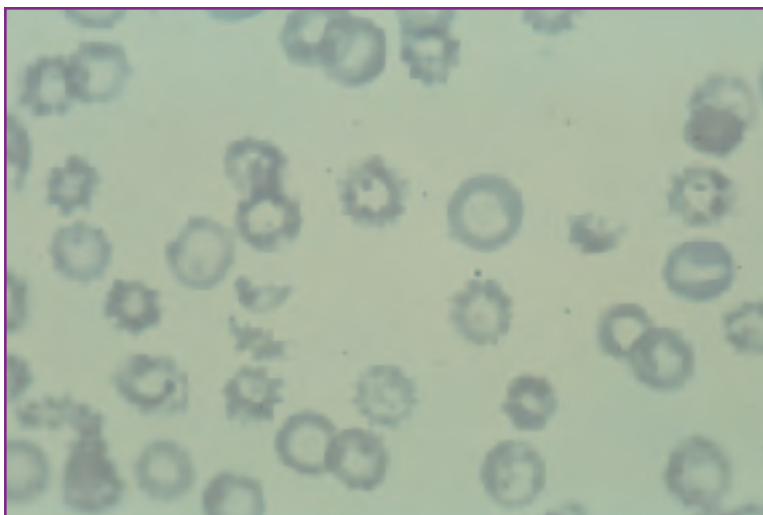
All of the hemolytic conditions described thus far have been characterized by either an intrinsically or extrinsically induced defect in the circulating red blood cells leading to shortened red cell lifespan. Shortened red cell lifespan can also occur when normal red blood cells are forced to circulate through abnormal vascular beds. This is microangiopathic hemolysis.

Microangiopathic hemolysis can occur in any condition where the morphology of capillary beds is altered, such as: disseminated intravascular coagulopathy, where capillary lumens are distorted by the deposition of fibrin; hemangiosarcoma, where there is localized intravascular coagulopathy; glomerulonephritis, where glomerular tuft architecture can be obliterated; and some cases of cardiac disease, where blood flow patterns can be markedly altered. Microangiopathic hemolysis with red cell fragmentation can also be a feature of heartworm disease.

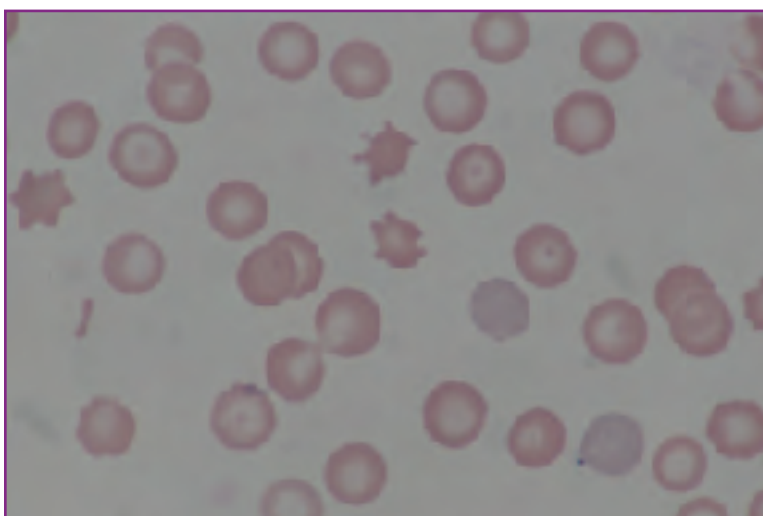
In dogs, microangiopathic hemolysis is characterized by the presence of red cell fragments called schizocytes (*Fig. 16*); in cats, fragments are rarely seen. The degree of anemia, and therefore, the degree of regeneration, is mild to moderate.

### ***Metabolic anemia with spiculated red cells***

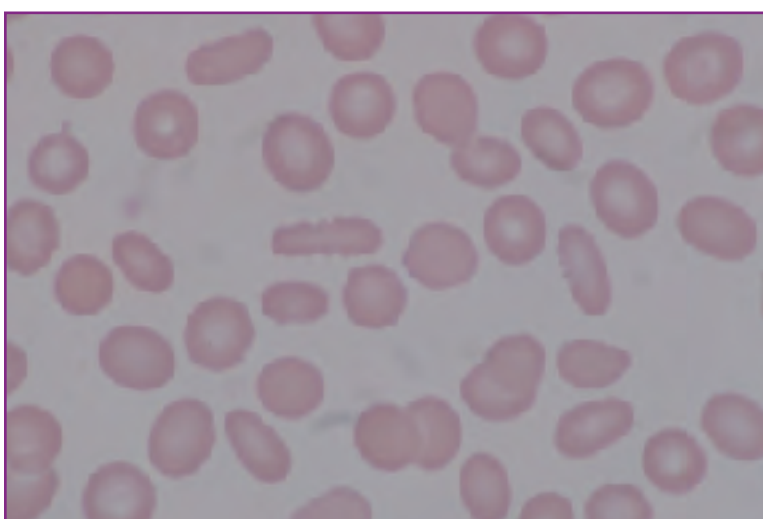
In dogs, anemias with spiculated red blood cells are associated with some cases of liver and kidney disease. These abnormal red cell shapes are probably caused by abnormal lipid metabolism and secondary altered plasma free cholesterol/phospholipid ratios. Abnormal plasma lipids equilibrate with the lipids in the red cell membrane and spiculated cells result. Spiculated red cells are less flexible than normal, thus some degree of hemolysis occurs. Despite the hemolytic component, these anemias are complex and generally non-regenerative because of the inability of the marrow to respond appropriately.



**Fig. 16** Microangiopathic hemolysis in disseminated intravascular coagulopathy (DIC). Numerous schizocytes.



**Fig. 17** Hepatic hemangiosarcoma in a dog. Two acanthocytes (center). A schizocyte (left). Numerous target cells, which can be precursors to acanthocytes, are also present. Polychromasia indicates a mildly regenerative anemia.



**Fig. 18** Canine glomerulonephritis. Numerous Burr cells.

Spiculated red cells are of two basic types: acanthocytes and burr cells. Acanthocytes are red cells with 2 to 10 blunt, elongated, finger-like projections on the red cell surface (Fig 17). Burr cells are oval-shaped red cells with ruffled margins (Fig. 18). Although both cell types can be seen with either liver or kidney disease, generally acanthocytes are associated with liver disease while burr cells are more common in kidney disease.

## Non-regenerative Anemias

Non-regenerative anemias can be grouped into two broad categories: maturation defect anemias and hypoproliferative anemias. In most cases, bone marrow evaluation is required to render a definitive diagnosis in either type of non-regenerative anemia.

### Maturation defect anemias

Maturation defect anemias are the result of acquired bone marrow abnormalities in which either nuclear or cytoplasmic development of red cell precursors is arrested. The defect may be in red cell precursors only or may affect all proliferating marrow cell lines. The marrow is generally hypercellular; however, since increased numbers of normal immature RBCs are not released into circulation, erythropoiesis is ineffective.

#### Nuclear maturation defect anemia

Nuclear maturation defect anemia is relatively common in cats but quite rare in dogs. Clinically, it is a mild to severe non-regenerative anemia with associated leukopenia and thrombocytopenia. Pancytopenia indicates a marrow disorder involving all cell lines.

Variable numbers of excessively large, fully hemoglobinized red cells (macrocytes) are observed on blood films. If these are numerous enough in the blood, MCV is elevated while MCHC remains normal. Occasional abnormal nucleated red cells may also be observed on blood films (Fig. 19). These are usually quite large with large immature nuclei but fully hemoglobinized cytoplasm. This morphology indicates arrested nuclear development in the marrow; these cells are termed megaloblasts.

Peripheral blood film morphology is suggestive of nuclear maturation defect anemia. However, for definitive diagnosis, marrow evaluation is

required. Marrow samples are hypercellular with increased activity in all cell lines. All cell lines feature arrested nuclear development with normal cytoplasmic development. Numerous megaloblasts are seen among the red cell precursors (Fig. 20). Granulocytes have normal cytoplasm but most nuclei are deficient in chromatin and rarely mature past the myelocyte stage. Megakaryocytes are smaller than normal and contain only one to two nuclei rather than the normal 8 to 16.

The most common cause of nuclear maturation defect anemia in cats is FeLV, which appears to interfere directly with DNA synthesis. In dogs, nuclear maturation anemia results from functional folic acid or vitamin B<sub>12</sub> deficiency. These can be true nutritional deficiencies—which is rare in animals—or drug-induced, resulting in folate block.

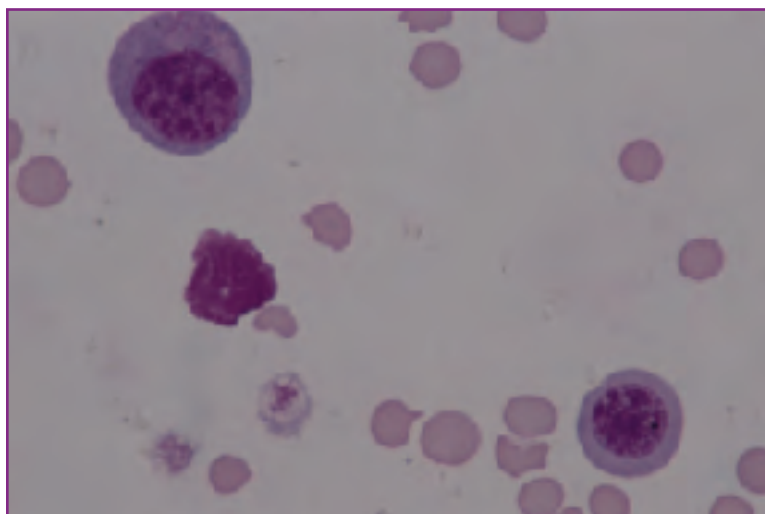


Fig. 19 FeLV (peripheral blood film). Two megaloblasts.

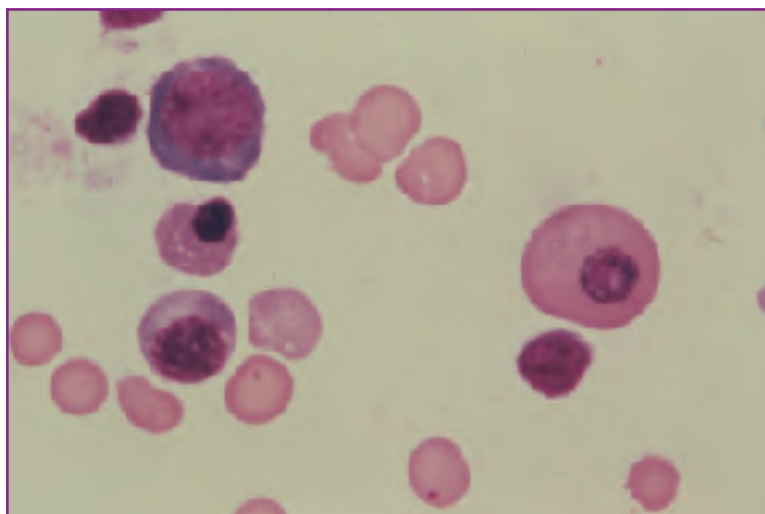
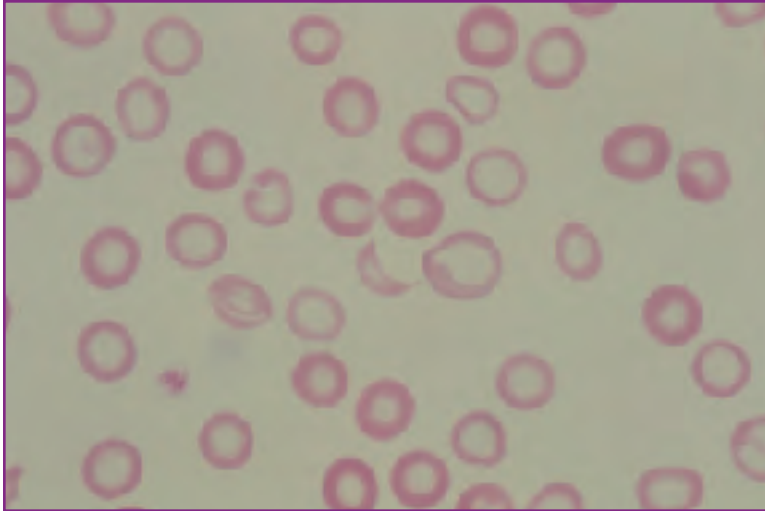


Fig. 20 Bone marrow smear from the same case as Fig. 19. A large megaloblast (right).



**Fig. 21** Iron deficiency anemia. Numerous red cells have exaggerated areas of central pallor; some are smaller than normal. A red cell fragment (schizocyte—center).

Chemotherapeutic agents such as methotrexate and dilantin are known folate antagonists.

### *Cytoplasmic maturation defect anemia*

Cytoplasmic maturation defect anemia is characterized by normal nuclear development but arrested cytoplasmic development (ie, lack of normal hemoglobinization). The main cause in all animals is iron deficiency. Iron deficiency anemia is the end stage of blood loss.

Iron deficiency anemia is morphologically distinctive, particularly in the dog. Red cells are smaller than normal and have exaggerated areas of central pallor. Red cell indices often feature reduced MCV and MCHC. Iron deficient red cells are more fragile than normal; blood films often have significant numbers of red cell fragments (*Fig. 21*).

### *Hypoproliferative anemias*

Non-regenerative hypoproliferative anemias are the most common anemias in domestic animals. In most cases, peripheral blood findings are nonspecific; bone marrow evaluation is essential for evaluation. Hypoproliferative anemias fall into four general categories: anemia of inflammatory disease, anemia due to reduced erythropoietin, myelophthitic anemia, and anemia due to marrow toxicity.

#### *Anemia of inflammatory disease*

The anemia of inflammatory disease is the most common of all anemic syndromes. It is a mild to moderate normocytic, normochromic, non-regenerative anemia with no dis-

tinctive morphologic features. Diagnosis is presumptive, based upon evidence of inflammatory disease, including an inflammatory leukogram. Bone marrow findings are supportive and include granulocytic hyperplasia, mild erythroid hypoplasia, plasma cell hyperplasia, and accumulation of hemosiderin (iron) in marrow macrophages.

#### *Anemia due to reduced erythropoietin*

In many cases of end-stage renal disease, erythropoietin production by the kidney is reduced. This results in normocytic, normochromic, non-regenerative anemia. In hypothyroid animals, there are also reductions in circulating erythropoietin primarily because of reduced metabolic demands for oxygen at the tissue level. Once again, the net effect is normocytic, normochromic, non-regenerative anemia.

### *Myelophthitic anemia*

Myelophthitic syndromes are conditions in which an aberrant cell population replaces normal bone marrow. Aberrant populations may be either benign (eg, fibrocytes in myelofibrosis) or malignant (eg, leukemia). Because of marrow replacement, cytopenia of one or more cell lines is typical in the peripheral blood. Anemias are severe and non-regenerative. Leukopenia often is also quite severe, but platelet numbers are more variable.

In most cases, peripheral red cell morphology is unremarkable. However, in some cases of myelofibrosis in dogs, poikilocytosis is marked. A particular form of poikilocyte, the dacryocyte, has been associated with myelofibrosis in dogs (*Fig. 22*). Dacryocytes are teardrop-shaped erythrocytes.

Whenever a myelophthitic syndrome is suspected (ie, whenever severe cytopenias are present), a bone marrow examination is indicated. Marrow aspirates in myelophthitic syndromes may be hypercellular and immediately diagnostic or hypocellular (dry tap) and nondiagnostic; therefore, both marrow aspirates and marrow core biopsies should be collected in suspected cases. Marrow aspirates from cases of myelofibrosis are always hypocellular.

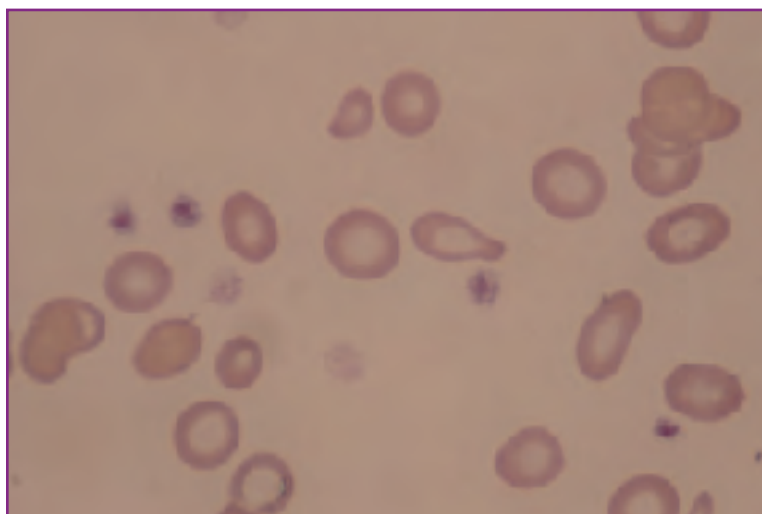
#### *Anemias due to marrow toxicity*

Marrow cytotoxicity can be caused by both infectious and noninfectious etiologies. Infectious causes include diseases such as canine and feline parvovirus infections, FeLV

infection, FIV infection, and canine ehrlichiosis. In addition to direct marrow cytotoxicity, some of these agents may cause secondary immune-mediated marrow suppression. Noninfectious causes of marrow toxicity include a variety of etiologies such as estrogen toxicity, cancer chemotherapeutic agents, and ionizing radiation.

The peripheral blood indicator of marrow toxicity is progressive cytopenia of one or more cell lines. Clinical signs depend upon which cell lines are affected and how severely. In the case of red cells, the degree of anemia can be quite severe and is non-regenerative. Patients with this kind of anemia are lethargic with extremely pale mucous membranes. Patients with severe thrombocytopenia may present with bleeding disorders while those with severe granulocytopenia may be presented because of secondary inflammatory conditions.

As with myelophthitic syndromes, bone marrow aspirates and core biopsies are required for diagnosis. In acute marrow toxicity, bone marrow necrosis may be seen histologically. Cytologic signs of acute toxicity in marrow precursor cells include cytoplasmic vacuolation and basophilia, nuclear vacuolation, bizarre nuclear shapes, and cytonu-



**Fig. 22** Myelofibrosis in the dog. A dacryocyte (center and top center) and numerous ovalocytes.

clear dissociation. In marrow toxicity of longer duration, the principal alteration is hypocellularity; this must be evaluated histologically with core biopsies. If the condition is characterized by hypocellularity of all cell lines, the condition may be termed an aplastic anemia. Prognosis in these cases is guarded.

# Chapter 3: Platelets in Health and Disease

## Overview

Platelets are the third cellular component of the peripheral blood; yet, they are often overlooked in both quantitative and qualitative peripheral blood evaluation. Since 90% or more of the bleeding disorders in dogs and cats result from abnormalities in platelet number or function, the clinical significance of these cells should not be underestimated. Furthermore, platelets contain a significant number of biologically active molecules that moderate such events as inflammation, neovascularization, thrombosis, hemostasis, fibrinolysis, and coagulation.

On routine blood films, platelets are recognized as small anucleate discoid cytoplasmic fragments containing variable numbers of purple granules. Ultrastructurally, they are much more complex. Shape is apparently maintained through the interaction of a cytoplasmic microtubular coil and an actin membrane skeleton located beneath the plasma membrane. The plasma membrane has numerous invaginations, which form the surface-connected canalicular system (SCCS). Central to the microtubular coil are the

principal platelet organelles: two types of granules (alpha and dense), the dense tubular system (DTS), mitochondria, lysosomes, and peroxisomes. (See *Fig. 1*)

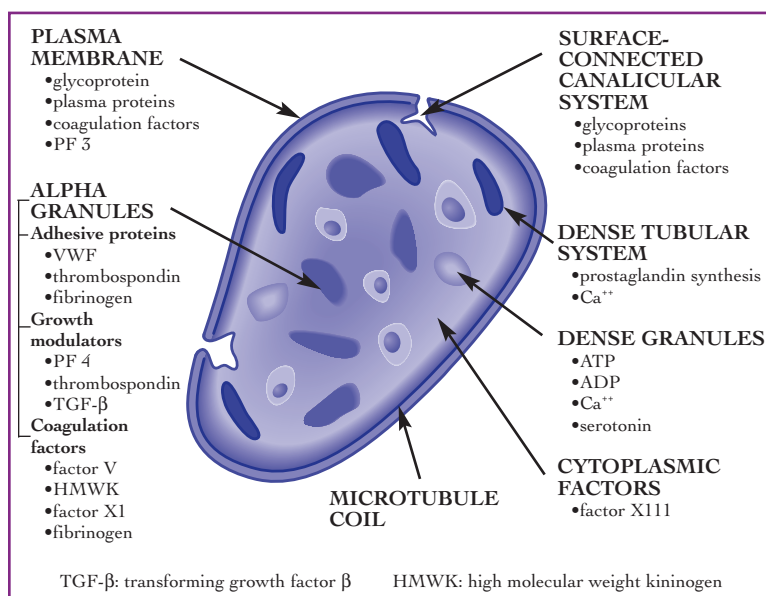
The plasma membrane and the SCCS are covered by a glycoprotein glycocalyx to which coagulation factors and plasma proteins such as immunoglobulins are adhered. Within the glycocalyx are receptors for the various platelet agonists that initiate the stages of platelet activation. The plasma membrane is rich in phospholipids, which give rise to prostaglandins and leukotrienes, important molecular mediators of the inflammatory milieu. The plasma membrane itself is also the main source of platelet factor 3 (PF 3), a coagulation co-factor.

Both types of platelet granules also contain a host of biologically active molecules that are important to blood clotting and other life processes, and are released during platelet activation. Dense granules are a source of ATP, ADP, serotonin, and calcium. Alpha granules contain and ultimately release platelet factor 4 (PF 4), von Willebrand's factor (VWF), fibrinogen, and coagulation factor V.

The DTS is derived from endoplasmic reticulum and is the probable site of platelet prostaglandin synthesis. Calcium, an important component in platelet aggregation, is also stored in high concentrations in the DTS.

## Production of Platelets

Like all circulating blood cells, platelets are bone marrow derived. The first recognizable platelet precursor is the megakaryoblast. Megakaryoblasts undergo endomitosis (nuclear division without cytoplasmic division) to form megakaryocytes. Megakaryoblasts have a DNA ploidy of 2N to 4N. Fully developed megakaryocytes may have a ploidy of up to 64N. Because these cells do not divide as they mature, the number of marrow megakaryocytes is relatively low. However, as they undergo endomitosis they become quite large and are easily recognized in both cytologic and histologic marrow preparations.



**Fig. 1** Ultrastructure of the platelet.

*Modified from Plow EF and Ginsberg MH: Molecular basis of platelet function. In Hoffman R, et al. (Eds): Hematology: Basic Principles and Practice. New York, Churchill Livingstone, 1991, pp 1165-1176.*

How platelets are actually formed from megakaryocytes remains unclear. The primary site of thrombopoiesis is also debated. There is some evidence that in some species the predominant site of platelet formation is in the lung rather than marrow. However, it is clear that platelet production is regulated by overall platelet mass in the body and not platelet numbers. A variety of growth factors are involved in the initial phase of megakaryocytopoiesis, including granulocyte-macrophage colony-stimulating factor (GM-CSF), interleukin 3 (IL 3), IL 6, and megakaryocyte colony-stimulating factor. Differentiation of megakaryocytes into platelets is also controlled by growth factors, including thrombopoietin, erythropoietin, GM-CSF, and IL 3. Platelets themselves contain biologically active molecules (eg, PF 4) which inhibit megakaryocyte production, suggesting that there also may be a negative feedback loop helping to regulate thrombopoiesis.

## Platelet Destruction

As with all other circulating cells, the platelet has a finite circulating lifespan. Dog platelets circulate for approximately five to seven days while cat platelets survive only a little more than a day. Cells of the monocyte/macrophage continuum are responsible for the removal of effete platelets. Nearly half are removed by splenic macrophages and a third by macrophages of the liver.

## Platelet Function

The primary role of the platelet is in hemostasis where it performs three functions:

- forming the primary platelet plug,
- serving as a scaffold for the deposition of fibrin, and
- influencing clot retraction.

In performing these functions, platelets undergo a complex series of events described collectively as platelet activation. Although the events of activation can be described sequentially, in reality, the process is a dynamic one with multiple events occurring simultaneously.

An early step in platelet activation is platelet adherence. Normally, circulating platelets will not adhere to intact vessel walls. However, when endothelial surfaces are compromised, platelets readily adhere to exposed subendothelial adhesive proteins including collagen, fibronectin, and VWF.

Exposure of platelets to thrombin, present as a result of simultaneous activation of the coagulation cascade, leads to a platelet shape change. Discoid platelets round up and develop numerous surface filaments called filopodia. The net effect is increased surface area, which serves to increase the likelihood of platelet-platelet interaction that is critical to platelet plug formation. Exposure to thrombin also causes granule secretion. Released ADP recruits other platelets into the area. Calcium released from platelets probably is important in coagulation reactions. Other granule contents released include: serotonin, which causes vascular contraction; additional adhesion molecules; promoters and inhibitors of coagulation; and growth promoters, which stimulate fibroblastic proliferation and connective tissue matrix formation.

When fibrinogen binds to activated platelets, aggregation, the final step in platelet plug formation, occurs. Initially, aggregation is a reversible reaction. However, with time the process becomes irreversible.

Platelet activation and platelet plug formation interfaces with the coagulation cascade in multiple ways. The platelet plug provides an expanded surface upon which the various enzymatic reactions of the cascade can occur. The binding of fibrinogen and thrombin to platelet surfaces further facilitates coagulation, as does the release of coagulation cofactors from platelets at the time of granule secretion. Factor XIII (fibrin stabilizing factor), an enzyme that catalyzes the cross-linking and stabilization of fibrin, is released from platelet cytoplasm at the time of granule release. The cross-linking of fibrin in conjunction with the interaction of the platelet fibrinogen receptor with platelet actin leads to clot retraction, the last step in coagulation.

## Platelet Disorders

Platelet disorders fall into two major categories: quantitative abnormalities and qualitative abnormalities.

Quantitative abnormalities include thrombocytosis and thrombocytopenia. These abnormalities, in particular, thrombocytopenia, are by far the most important and prevalent, and are covered in some detail below.

Qualitative abnormalities include: hereditary platelet function defects in von Willebrand's Disease, Chediak Higashi Syndrome, and hereditary canine thromboasthenia; and acquired function defects associated with certain drug therapies and systemic diseases. Qualitative abnormalities

are diagnosed when other causes of bleeding have been ruled out. In general, platelet functional deficits cannot be diagnosed from routine hematologic data and require the performance of special tests. They are beyond the scope of this text and, therefore, will not be discussed.

## Thrombocytopenia

Thrombocytopenia, or reduction in the number of circulating platelets, is caused by one of four mechanisms:

- increased peripheral utilization of platelets,
- increased destruction of platelets,
- increased sequestration of platelets, or
- reduced platelet production in the bone marrow.

These are summarized in *Fig. 2*.

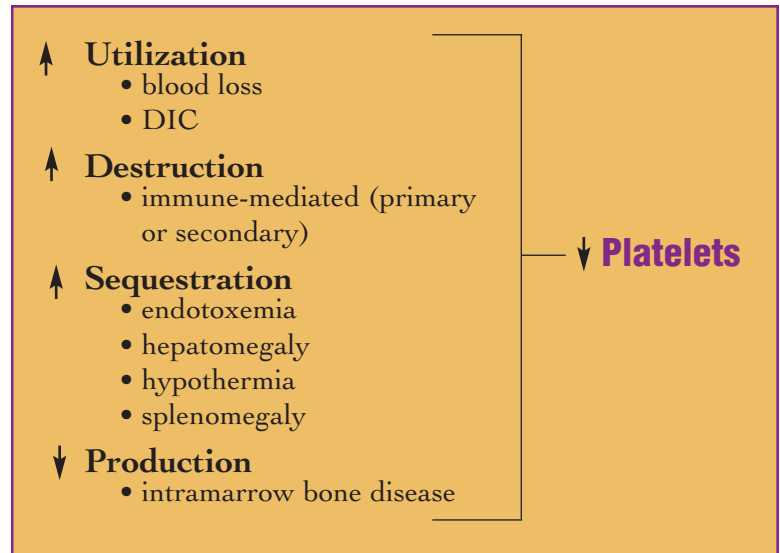
### *Increased peripheral utilization*

Increased peripheral utilization results when there is increased systemic demand for platelets. This occurs in two conditions: disseminated intravascular coagulopathy (DIC) and blood loss.

DIC is a secondary syndrome associated with underlying severe disease. In most cases, the underlying process is inflammatory, but DIC also occurs in some cases of neoplasia, marked tissue necrosis and shock. Regardless of the inciting cause, DIC is a syndrome where excessive stimulation of the coagulation cascade leads to the peripheral consumption of both coagulation factors and platelets.

Clinically, animals with fully developed DIC often present as emergency patients with bleeding disorders. Subclinical DIC syndromes also occur. Laboratory findings can include thrombocytopenia, prolonged activated partial thromboplastin time (APTT) and one step prothrombin time (OSPT), decreased fibrinogen levels, and elevated fibrin split products. When any three of the above laboratory abnormalities are present, the diagnosis of DIC is confirmed. In dogs, an additional laboratory finding may be the presence of schizocytes on the peripheral blood film. Schizocytes are rarely seen in cats with DIC.

Thrombocytopenia secondary to blood loss is mild. If severe thrombocytopenia (platelet counts of 40,000/ $\mu$ l or less) is seen in association with blood loss, the thrombocytopenia is probably the cause rather than the result of the hemorrhage.



**Fig. 2** The four mechanisms of thrombocytopenia.

### *Increased platelet destruction*

Like utilization thrombocytopenia, destruction thrombocytopenia is associated with shortened circulating platelet lifespan, but in this case, as a result of immune-mediated removal. As with immune-mediated hemolysis, immune-mediated thrombocytopenia may be a true autoimmune syndrome caused by circulating antiplatelet antibodies, or it may be secondary to drug therapy, infectious diseases, or neoplasia.

For the general practitioner, the specific diagnosis of immune-mediated thrombocytopenia can be challenging. The degree of thrombocytopenia is usually marked, with counts of 20,000/ $\mu$ l or less. Bone marrow aspirates can be taken to estimate megakaryocyte numbers. Most cases of immune-mediated thrombocytopenia are characterized by increased numbers of megakaryocytes, although rare cases have reduced numbers. Utilization thrombocytopenia also has either normal or increased numbers of megakaryocytes. Clinical signs, history, and other laboratory data, including coagulation tests, are useful in ruling out utilization thrombocytopenia, thereby allowing a presumptive diagnosis of immune-mediated thrombocytopenia. Special tests for immune-mediated thrombocytopenia (eg, PF 3 test, antimegakaryocyte antibody test) may be considered, though the value of these tests is controversial.

Once other causes of thrombocytopenia have been ruled out and a presumptive diagnosis of immune-mediated thrombocytopenia is made, immunosuppressive therapy can be instituted. If successful, the therapy itself serves to confirm the diagnosis.

---

### *Sequestration thrombocytopenia*

Thrombocytopenia can occur in cases of hepatomegaly or splenomegaly as a result of sequestration of platelets in the enlarged organs. This condition is much more common in humans than in animals, and is very rare in dogs and cats. Hypothermia has been demonstrated to cause platelet sequestration in the liver. Thrombocytopenia in endotoxemia is believed to be at least partially the result of sequestration in the lung.

### *Hypoproliferative thrombocytopenia*

Hypoproliferative thrombocytopenia is the direct result of reduced megakaryocytopoiesis. In most cases, there is reduced production of at least one other cell line; hemograms generally reflect anemia and/or leukopenia in addition to thrombocytopenia. Bone marrow biopsies reveal reduced numbers of precursors of each of the affected cell lines. Both aspirates and core biopsies are usually required for proper evaluation. The specific cause is often obscure and may include infectious diseases, drug toxicity or myelosuppression, myelofibrosis, immune-mediated marrow disease, and cancer.

### **Thrombocytosis**

Thrombocytosis is defined as increased numbers of circulating platelets. Clinically, it is much less common than thrombocytopenia. In the dog and cat, most cases of throm-

bocytosis are secondary or reactive. Thrombocytosis can be seen secondary to splenic contraction (eg, with excitement or exercise), elevated circulating glucocorticoids, splenectomy, or fractures. For the most part, reactive thrombocytosis is clinically insignificant.

Thrombocytosis also can occur as a feature of several primary bone marrow diseases. Primary platelet leukemia is a true myeloproliferative disorder. In the cat, it may be FeLV related. Platelet leukemia can manifest in either of two forms: primary thrombocythemia with very high numbers of circulating platelets, or megakaryoblastic leukemia with variable numbers of circulating platelets but massive proliferation of platelet precursors in marrow and usually other tissues. In both conditions, platelets with bizarre morphology may be seen in the peripheral blood.

Polycythemia vera is a second myeloproliferative disorder which can be characterized by thrombocytosis. Polycythemia vera is a stem cell defect which is characterized by overproduction of all cell lines. The degree of overproduction is relatively subtle; evaluation of marrow biopsies generally reveals no abnormalities.

As discussed in Chapter 2, myelofibrosis is a marrow disorder that can be characterized by either thrombocytopenia or thrombocytosis. Other presenting features are used to establish the diagnosis; these include marked non-regenerative anemia, leukopenia, and poikilocytosis with dacryocytes on the peripheral blood film.





# Chapter 4: Hemogram Interpretation

## Overview

Hemogram interpretation, or evaluation of the peripheral blood, is one of the foundations of clinicopathologic assessment of the sick patient, both from the perspective of making the initial diagnosis and prognosis, and from the perspective of monitoring response to therapy. Hemogram interpretation is an integrated evaluation of the various tests of the complete blood count (CBC), which consists of white blood cell data, red blood cell data, and platelet data.

The CBC has both qualitative and quantitative components. The qualitative component is the evaluation of blood cell morphology on the peripheral blood film. The quantitative components include all the numerical measures in the CBC: total cell counts, white cell differential, hematocrit, hemoglobin, red cell indices, and total plasma protein.

Accurate hemogram interpretation is based on a clear understanding of the physiology and pathophysiology of the various components of the hematopoietic system. In the previous three chapters, white cell, red cell, and platelet responses in health and disease were reviewed and illustrated. This chapter will develop a systematic approach to CBC interpretation built around this basic information. In many instances, the reader will be referred to appropriate pages in the preceding chapters for further detail.

In evaluating the CBC, white cell data are always interpreted first, followed by interpretation of red cell data, and finally platelet data. This order is logical since abnormalities in white cell data may suggest potential red cell and platelet alterations.

## Interpreting the Leukogram

White cell data in the CBC include the total white cell count, the differential cell counts, and evaluation of white cell morphology on the peripheral blood film. All cell counts should be reported in absolute numbers. The primary value of white cell data is in recognizing and classifying inflammatory responses. Considered collectively, leukogram data are used to address the following questions:

1) Is there evidence of inflammation?

- 2) Is there evidence of a glucocorticoid (stress) response?
- 3) Is there evidence of an epinephrine (excitement) response?
- 4) Is there evidence of a systemic hypersensitivity reaction?
- 5) Is there evidence of tissue necrosis?
- 6) If inflammation is present, can it be further classified?
- 7) Is there evidence of systemic toxemia?

## Is there evidence of inflammation?

Reference ranges for total white cell count and differential cell counts in dogs and cats are found in **Table 1** at the back of this book (Part III). The signposts of inflammation are a neutrophilic left shift, persistent eosinophilia, and/or a monocytosis. These can be seen individually or in any combination. Monocytosis and eosinophilia are easily recognized as any value above the reference range. Identification of neutrophilic left shifts is somewhat more subjective. Left shifts are usually defined in relationship to total neutrophil or WBC count. As a guide, if the total white cell count is normal, a count of greater than 300 bands/ $\mu\text{l}$  constitutes a left shift. If the total white cell count is 25,000/ $\mu\text{l}$  to 30,000/ $\mu\text{l}$ , at least 1000 bands/ $\mu\text{l}$  are required to designate a left shift. If the total white cell count is below normal, fewer than 300 bands/ $\mu\text{l}$  indicates a left shift.

Based on the above criteria, it should be clear that total white cell count alone cannot determine whether or not inflammation is present. Inflammation can be present in the face of low, normal, or high total white cell count. Total white cell count is primarily an indicator of balance between bone marrow production and two other key factors; the release of granulocytes and tissue demand for leukocytes. A normal white cell count indicates that the balance between marrow production and release of granulocytes and tissue utilization is being maintained. Elevated white cell counts indicate increased bone marrow production and granulocyte release relative to tissue demand. Reduced white cell counts indicate that leukocytes are marginating along vessel walls and moving into the tissues at greater rates than they are being produced and released

into the blood from the marrow. Classification of an inflammatory response as active, chronic, or overwhelming depends upon which of these dynamic states exists. This will be discussed in greater detail later in this chapter.

Inflammatory responses can also occur without any of the classic signposts; in these cases the leukograms are ambiguous. For example, a mild, mature neutrophilia may be the result of inflammation, however, it also may be due to other factors, such as high circulating glucocorticoid levels. In these cases, repeat CBCs done at 6- to 12-hour intervals may help clarify the response. In inflammatory diseases, left shifts are common.

### **Is there evidence of stress?**

The classic stress (glucocorticoid-induced) leukogram includes: mild, mature neutrophilia, lymphopenia, eosinopenia, and mild monocytosis. Of these changes, only the lymphopenia is specific. In dogs and cats, lymphocyte counts of between 700/ $\mu$ l and 1500/ $\mu$ l are consistent with a glucocorticoid effect. Lymphocyte counts of less than 700/ $\mu$ l may be partially the result of stress, but other causes of lymphopenia must be explored. These include lymphoma, chylous effusions, and lymphatic obstruction.

When a stress leukogram is present, other alterations in the hemogram and clinical chemistry panel can be anticipated. There may be mild polycythemia as well as mild inappropriate nucleated red cell response (5 to 10 nucleated red cells/100 white cells counted). Isosthenuria is a common finding. Mild hyperglycemia (120 mg/dl to 180 mg/dl) is typical and there are often mild to moderate elevations in serum transaminases. If the leukogram is a result of Cushing's disease, elevations in alkaline phosphatase (dog only) may be marked (more than four times the upper range of normal).

### **Is there evidence of excitement?**

Excitement causes the release of epinephrine; epinephrine, in turn, causes increased blood flow. Increased blood flow washes marginating leukocytes off vessel walls and back into circulation where they can be collected and counted. In dogs and cats, under normal circumstances, the ratio of freely circulating to marginating cells is 1:1. Theoretically, therefore, epinephrine release has the potential to double the total white cell count. In dogs, excitement leukocytosis is primarily the result of neutrophilia while in cats, it is usually the result of lymphocytosis.

Epinephrine-induced leukocytosis occurs as soon as

blood flow increases, and disappears just as rapidly when blood flow returns to normal. This is in direct contrast to the glucocorticoid response, which takes approximately four hours to develop and lasts for approximately 24 hours.

### **Is there evidence of a systemic hypersensitivity reaction?**

Persistent eosinophilia is not only indicative of inflammation; it is also suggestive of systemic hypersensitivity. For a more in-depth discussion of the interpretation of eosinophilia and a listing of possible causes, refer to Chapter 1, page 6.

### **Is there evidence of tissue necrosis?**

Tissue necrosis is presumed to be present whenever there is peripheral monocytosis. For a more complete discussion of monocytosis, turn to Chapter 1, page 8.

### **If inflammation is present, can it be further classified?**

In dogs and cats, acute or active inflammation is characterized by rapid movement of neutrophils from bone marrow to the site of involvement in the tissues. In most cases, because of the large marrow reserve of neutrophils, the rate of entrance of neutrophils into the blood generally exceeds the rate of exit into the tissues; therefore, the white cell (neutrophil) count is usually elevated. At the same time, because of the high demand for neutrophils, immature neutrophils (band cells) will also be drawn into the blood. Thus, neutrophilia with a left shift (a regenerative left shift) is the typical and appropriate neutrophil response in acute inflammation. Tissue necrosis is a variable accompaniment, so monocytosis may or may not also be present. Because animals with acute inflammatory disease are almost always under stress, there is almost always lymphopenia.

Occasionally, in acute inflammatory conditions, tissue utilization is greater than the ability of the marrow to keep pace with demand. This constitutes overwhelming inflammation and the prognosis is guarded. In these cases, total white cell count and neutrophil count are reduced and there is a left shift (degenerative left shift). Changes in lymphocyte counts and monocytes are as described above.

If acute inflammation continues unresolved, it gradually enters a chronic phase with leukogram features to match. Circulating half-life of neutrophils remains short, but over time expanded marrow production equilibrates with the high turnover rate. Eventually a new steady state is estab-

lished. The net effect is that neutrophil numbers return to near normal and the left shift disappears. Animals with chronic inflammatory conditions continue to be stressed (lymphopenia) but at the same time often have antigenic stimulation (lymphocytosis). The net effect is a normal to slightly elevated lymphocyte count. Because of tissue necrosis and the ongoing demand for phagocytosis, the most consistent abnormal finding in chronic inflammatory leukograms is monocytosis.

It is important to note that not all cases of inflammatory disease have leukograms that fall neatly into these described patterns. In addition, the separation of responses into acute and chronic is somewhat arbitrary, as leukogram data cannot be used to judge the duration of a disease process. For example, the length of time required for bone marrow production to equilibrate with tissue utilization will vary from case to case. Nevertheless, once the presence of inflammatory disease has been established, certain other possible hemogram changes should also be considered.

The most common red cell accompaniment to inflammatory disease is anemia. The anemia is mild to moderate and non-regenerative. In dogs, hematocrits are between 30% and 40%. In cats, hematocrits may drop to as low as 25%. Anemia with these features in association with inflammatory leukograms is considered to be the anemia of inflammatory disease. The anemia of inflammatory disease has generally been regarded as a chronic condition; however, in cats, it can develop in a week or less. In the dog, slightly more time is required because of the longer red cell lifespan. See Chapter 2 for more information on anemias.

Inflammatory diseases, particularly chronic ones, are often associated with increased immunoglobulin production by the specific immune system. In the hemogram, this is seen as hyperproteinemia. Hypergammaglobulinemia can be confirmed by evaluating total protein and albumin in the serum chemistry panel.

Whenever inflammatory leukograms are present, particularly if overwhelming or marked, special attention should be given to platelet numbers. If platelet numbers are reduced, the possibility of DIC should be considered. The blood film should be scanned for schizocytes. Completion of a DIC panel (see Chapter 3, page 29) is indicated.

### **Is there evidence of systemic toxemia?**

Systemic toxemia occurs when circulating toxins of either infectious or noninfectious origin interfere with the differentiation of neutrophil precursors in the marrow. The

result is the presence of toxic neutrophils on peripheral blood films. These have been described and illustrated in detail in Chapter 1. Systemic toxemia is a poor prognostic sign.

## **Interpreting the Erythrogram**

Red cell tests in the CBC include total red cell count, hemoglobin, hematocrit, red cell indices (MCV, MCHC), total protein, and evaluation of red cell morphology on the blood film. Red cell count, hemoglobin, and hematocrit are measures of red cell mass or oxygen carrying capacity of the blood. Total protein provides immediate information about state of hydration, which can be very important in interpreting red cell mass. Elevations in total protein are most commonly the result of dehydration, which can falsely elevate indicators of red cell mass. The only other common cause of hyperproteinemia is hypergammaglobulinemia in inflammation.

As with leukogram data, erythrogram data are best interpreted by answering a series of questions:

- 1) Is red cell mass increased (polycythemia), decreased (anemia), or normal?
- 2) If increased, is the polycythemia relative or absolute?
- 3) If polycythemia is absolute, is it primary or secondary?
- 4) If red cell mass is decreased, is the anemia regenerative or non-regenerative?
- 5) If regenerative, is the mechanism blood loss or hemolysis?
- 6) If non-regenerative, can the mechanism be determined without bone marrow evaluation?

### ***Is red cell mass increased, decreased, or normal?***

This simple but all-important question is answered by evaluating the primary indicators of red cell mass (RBC count, Hb, HCT). Increases indicate polycythemia; decreases indicate anemia.

### ***If increased, is polycythemia relative or absolute?***

The combination of elevated hematocrit and elevated plasma protein is highly suggestive of dehydration and relative polycythemia. Dehydration can be confirmed on the basis of history, physical evaluation, and clinical chemistry. Clinical chemistry findings which are supportive of dehydration include elevated blood urea nitrogen (BUN) in

conjunction with concentrated urine specific gravity (prerenal azotemia), high normal or elevated albumin, and high normal or elevated serum electrolytes. In the absence of such indicators of dehydration, polycythemia is absolute.

***If polycythemia is absolute, is it primary or secondary?***

Secondary polycythemia is ruled out first. As suggested in Chapter 2, polycythemia can be associated with primary renal disease, cardiovascular or pulmonary disease, Cushing's disease, or neoplastic disease of the kidneys, either primary or metastatic. In the absence of such conditions, polycythemia is considered to be primary (**polycythemia vera**). Evaluation of arterial blood gas values and determination of erythropoietin levels will confirm the presence of polycythemia in the face of normal oxygenation of the blood and normal hormonal stimulation of the red cell marrow.

***If red cell mass is decreased, is anemia regenerative or non-regenerative?***

The first step in classifying an anemia is evaluation of the peripheral blood film. If there is increased anisocytosis and polychromasia, the anemia is likely regenerative. Regeneration can be confirmed by doing a reticulocyte count; absolute reticulocyte counts of greater than 80,000/ $\mu\text{l}$  are indicative of regenerative anemia in both dogs and cats.

***If regenerative, is the mechanism blood loss or hemolysis?***

History, clinical signs, physical examination, and reticulocyte count are the first data evaluated in differentiating blood loss from hemolysis. Most animals with blood loss anemia have histories of trauma or visible bleeding. History or clinical signs of vomiting, diarrhea, or marked external parasitism also are compatible with blood loss. Hemoglobinuria, hemoglobinemia, or marked reticulocytosis (greater than 200,000/ $\mu\text{l}$ ) are highly suggestive of hemolysis.

In all cases where blood loss is not clearly the cause of the regenerative anemia, care should be taken to evaluate the peripheral blood film for abnormal red cells. The morphologic signposts of hemolysis have been described and illustrated in detail in Chapter 2; they include spherocytosis, the presence of etiologic agents on red cells (hemobar-

tonellosis, babesiosis), the presence of Heinz bodies, and the presence of schizocytes.

***If non-regenerative, can the mechanism be determined without bone marrow evaluation?***

The most common of all anemias in dogs and cats is the anemia of inflammatory disease. If the anemia is mild to moderate and there is an inflammatory leukogram, the anemia of inflammatory disease is diagnosed. If there is significant renal disease, non-regenerative anemia associated with lack of erythropoietin is often seen. If there is marked hypochromasia and microcytosis (indicated by red cell indices and/or red cell morphology on the blood film, see Chapter 2), then iron deficiency anemia can be diagnosed.

All other non-regenerative anemias require bone marrow evaluation for definitive diagnosis. There are, however, syndromes where CBC findings and peripheral blood film morphology can be suggestive of non-regenerative anemia. These include myelofibrosis, characterized by severe anemia, leukopenia, variable platelet response and dacryocytes on peripheral films, and megaloblastic anemia where giant RBCs and even megaloblasts can be seen on peripheral films (see Chapter 2).

## **Interpreting the Thrombogram**

The only platelet tests in the routine CBC are evaluation of platelet numbers and platelet morphology on the peripheral blood film. As discussed in Chapter 3, platelet disorders are either quantitative or qualitative. Using the routine tests in the CBC, only quantitative disorders can be evaluated. The questions to be addressed are the following:

- 1) Are platelet numbers normal, increased (thrombocytosis), or decreased (thrombocytopenia)?
- 2) If there is thrombocytosis, is it reactive or primary?
- 3) If there is thrombocytopenia, can the mechanism be determined?

***Are platelet numbers normal, increased, or decreased?***

The answer to this question is, of course, based on platelet count, with a note of caution: automated platelet counts in cats are often inaccurate because of platelet clumping and the overlap of platelet and red cell sizes. Particularly in cats, platelet numbers should be estimated from blood films (adequate versus low) as well as counted

---

in an automated system. If discrepancies exist between estimates and automated counts, hand counts using Unopette® (Becton-Dickinson, Rutherford, NJ) methods should be completed. In general, extended hematocrit methods are more accurate at determining platelet counts in cats than are impedance methods.

***If there is thrombocytosis, it is reactive or primary?***

Reactive or secondary thrombocytosis is by far most common. Reactive thrombocytosis is discussed in Chapter 3, page 30. When causes of reactive thrombocytosis have been ruled out, primary thrombocytosis due to platelet leukemia must be considered. Bone marrow biopsies will probably be required for confirmation but platelet morphology on the blood film should be closely scrutinized. In most platelet leukemias, bizarre platelets are seen in the peripheral blood.

***If there is thrombocytopenia, can the mechanism be determined?***

Thrombocytopenic mechanisms are discussed in detail in Chapter 3 and are merely summarized here from a diagnostic perspective.

Thrombocytopenia in conjunction with inflammatory

leukograms and the presence of schizocytes and neutrophil toxicity on blood films is suggestive of utilization thrombocytopenia associated with DIC. The DIC panel should be run for confirmation (see Chapter 3). The possibility of sequestration thrombocytopenia is suggested by clinical evidence of hepatosplenomegaly. Destruction (immune-mediated) thrombocytopenia may be found in association with immune-mediated hemolytic anemia (highly regenerative spherocytic anemia) or without other hematologic abnormalities. Evidence of megakaryocytic hyperplasia in the bone marrow is helpful in establishing a diagnosis of destruction thrombocytopenia, but such evidence may be absent. Occasional cases of destructive thrombocytopenia show decreased numbers of megakaryocytes.

It is noteworthy that destruction thrombocytopenias, like sequestration thrombocytopenia, may be associated with hepatosplenomegaly. Hypoproliferative thrombocytopenia may be associated with other peripheral cytopenias, but can only be diagnosed by reduced numbers of megakaryocytes in marrow biopsies (histopathology of core biopsies required). The causes of hypoproliferative thrombocytopenia are varied and include infectious agents (eg, ehrlichiosis), immune-mediated marrow disease, marrow toxicity, marrow aplasia, and myelophthisis.

## CASE 1

**Signalment:** Three-year-old female DSH cat

**History:** Presented for elective surgery

HCT	38%	WBC	18,600/ $\mu$ l
Hb	12.5 g/dl	Neutrophils	8,000/ $\mu$ l
RBC	$7.2 \times 10^6$ / $\mu$ l	Lymphocytes	10,000/ $\mu$ l
TP	6.2 g/dl	Eosinophils	300/ $\mu$ l
Platelets	Adequate	Monocytes	300/ $\mu$ l

### Description

**Leukogram:** There is a leukocytosis characterized by a marked lymphocytosis. Neutrophil numbers are within the reference range.

**Erythrogram:** Red cell parameters and plasma protein are in the reference range.

**Thrombogram:** Unremarkable.

### Interpretation

The principal hematologic alteration is leukocytosis characterized by lymphocytosis.

Lymphocytosis in cats can be associated with several conditions such as lymphocytic leukemia, chronic antigenic stimulation, or physiologic leukocytosis.

Almost all cases of leukemia are characterized by marked anemia, but in this patient, red cell mass is normal. Furthermore, in most cases of lymphocytosis due to lymphocytic leukemia, circulating lymphocytes are morphologically abnormal, but no abnormal morphology is noted in this patient. Therefore, the possibility of lymphocytic leukemia is extremely low.

Chronic antigenic stimulation with lymphocytosis is usually associated with an inflammatory leukogram, but there is no evidence of inflammation in this cat. Consequently, the most likely interpretation here is physiologic leukocytosis.

Physiologic leukocytosis results from the effects of excitement (release of epinephrine) on blood flow; the effect being increased blood flow.

Under normal conditions, for every leukocyte freely circulating in the blood, there is one leukocyte marginated on the blood vessel walls. Theoretically, only freely circulating leukocytes are collected when a blood sample is drawn. However, due to the excitement (ie, epinephrine release) that is often associated with a blood draw, there is increased blood flow, which causes movement of marginated leukocytes into the freely circulating blood. This, then, can result in a doubling of the total leukocyte count.

In cats, the result is physiologic lymphocytosis. In dogs, physiologic neutrophilia generally results.

Physiologic leukopenia can also be seen in those circumstances where blood flow is decreased. Perhaps the best example is the effect of anesthesia. In this case, the number of leukocytes in the freely circulating blood is reduced as more and more cells marginate in the face of decreased heart rate and decreasing blood flow.

## CASE 2

**Signalment:** One-year-old female  
Wirehair Terrier

**History:** Presented for  
ovariohysterectomy

HCT	45%	WBC	20,300/ $\mu$ l
Hb	15.0 g/dl	Neutrophils	18,000/ $\mu$ l
RBC	$6.1 \times 10^6$ / $\mu$ l	Lymphocytes	1,500/ $\mu$ l
TP	6.5 g/dl	Monocytes	500/ $\mu$ l
Platelets	Adequate	Eosinophils	300/ $\mu$ l

### Description

**Leukogram:** There is a leukocytosis (mild) characterized by a mild mature neutrophilia and a low normal to marginally decreased lymphocyte count.

**Erythrogram:** No abnormalities noted.

**Thrombogram:** No abnormalities noted.

### Interpretation

Only white cell changes are observed. Unfortunately, these findings are somewhat ambiguous.

The marginal lymphocyte count suggests the possibility of a stress (glucocorticoid-induced) leukogram. A mild leukocytosis with mild mature neutrophilia also could be consistent with stress.

However, a mild mature neutrophilia could be a reflection of mild inflammation even though no specific indicators of inflammation are present. Repeating the CBC in 8 to 12 hours would be expected to clarify the presence or absence of inflammation.

Finally, the mild leukocytosis with neutrophilia is consistent with physiologic leukocytosis in the dog. Considering the history and signalment, stress with physiologic leukocytosis is the best interpretation.



## CASE 3

**Signalment:** Eight-year-old Boston Terrier

**History:** Polyuria and polydipsia of several weeks' duration

HCT	55%	WBC	14,500/ $\mu$ l
Hb	18.0 g/dl	Neutrophils	13,000/ $\mu$ l
RBC	$8 \times 10^6$ / $\mu$ l	Lymphocytes	750/ $\mu$ l
TP	6.5 g/dl	Monocytes	850/ $\mu$ l
NRBC	5/100 WBC	Platelets	Adequate

### Description

**Leukogram:** There is a normal leukocyte count but an absolute lymphopenia and marginal neutrophilia.

**Erythrogram:** There is a polycythemia in the face of a normal plasma protein (absolute polycythemia). There is also a marginal inappropriate nucleated red cell response (increased numbers of NRBC in the absence of polychromasia).

**Thrombogram:** Unremarkable.

### Interpretation

Leukogram data (absolute lymphopenia of between 700/ $\mu$ l and 1500/ $\mu$ l and marginal neutrophilia) are consistent with a glucocorticoid-induced leukogram. There is no evidence of superimposed inflammation or tissue necrosis.

Absolute polycythemia with a possible inappropriate nucleated red cell response also is entirely consistent with high levels of circulating glucocorticoids. Glucocorticoids are known to have a mildly stimulatory effect on RBC production. High circulating glucocorticoids also are one of the recognized causes of mild inappropriate nucleated red cell responses (5 to 10 NRBC/100 WBC).

Considering the history and signalment (Boston Terriers are prone to endocrinopathies) in conjunction with hematologic findings, Cushing's disease, either spontaneous or iatrogenic, should be investigated further.

## CASE 4

**Signalment:** Six-year-old intact female Poodle

**History:** Recent onset emesis, anorexia, polydipsia, and polyuria

HCT	30%	WBC	24,900/ $\mu$ l
Hb	10.0 g/dl	Bands	3,000/ $\mu$ l
RBC	$4.7 \times 10^6$ / $\mu$ l	Neutrophils	18,000/ $\mu$ l
TP	6.5 g/dl	Lymphocytes	900/ $\mu$ l
Platelets	Adequate	Monocytes	3,000/ $\mu$ l

**Morphology:** Foamy, basophilic cytoplasm in bands, occasional Döhle bodies.

### Description

**Leukogram:** There is a leukocytosis characterized by a neutrophilia with a left shift, a lymphopenia, and a monocytosis. Morphologic abnormalities in neutrophils also are noted on the blood film.

**Erythrogram:** Red cell data indicate a mild anemia characterized by an absence of polychromasia. Computed MCV (HCT/red cell count in millions  $\times$  10) and MCHC (Hb/HCT  $\times$  100) are within the reference range for dogs.

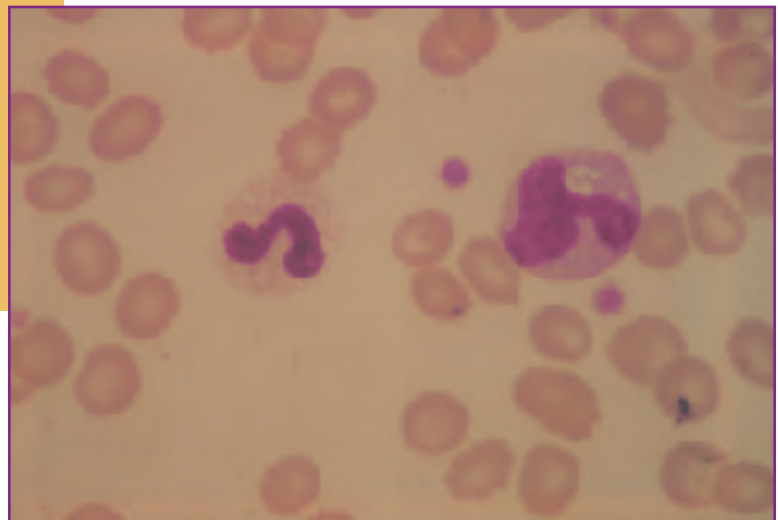
**Thrombogram:** Unremarkable.

## Interpretation

1.) Inflammatory leukogram with systemic toxemia. Indicators of inflammation are both the left shift and the monocytosis. Monocytosis is also an indication of tissue necrosis. Cytoplasmic basophilia and Döhle bodies in neutrophils result from cytoplasmic maturation arrests in developing stages in the marrow; this is indicative of circulating toxins in the blood which interfere with differentiation of granulocyte precursors (systemic toxemia). Systemic toxemia can occur as a result of tissue necrosis and toxic disorders (eg, lead poisoning) but in dogs and cats is most commonly associated with severe bacterial infections.

2.) Superimposed stress. The lymphocyte count of between 700/ml and 1500/ml (absolute lymphopenia) is indicative of stress. The combination of stress and inflammation with a left shift is most consistent with active or acute inflammation.

3.) Non-regenerative anemia. Normocytic, normochromic anemia in the absence of polychromasia is a non-regenerative anemia. The degree of anemia is moderate. Considering the presence of a significant inflammatory leukogram, at least part of the anemia is likely due to inflammatory disease. However, the degree of anemia is more severe than usually associated with inflammation



**Fig. 1** Band cell with slight toxicity (left). Note the foamy, granular, slightly basophilic cytoplasm. A normal monocyte (right).

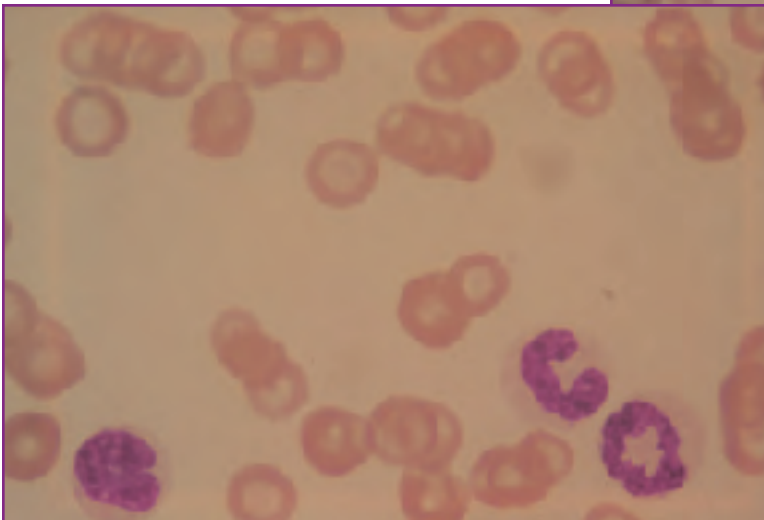
alone, which rarely reduces hematocrits in dogs to less than 35%. Other contributing factors, such as superimposed blood loss, must also be considered.

4.) Normal platelet count. The normal platelet count is a significant finding in this case. It is an encouraging finding in the face of the rather marked inflammation with evidence of systemic toxemia. A concern in severe inflammatory conditions is disseminated intravascular coagulation (DIC); the normal platelet count suggests that DIC is not currently a problem.

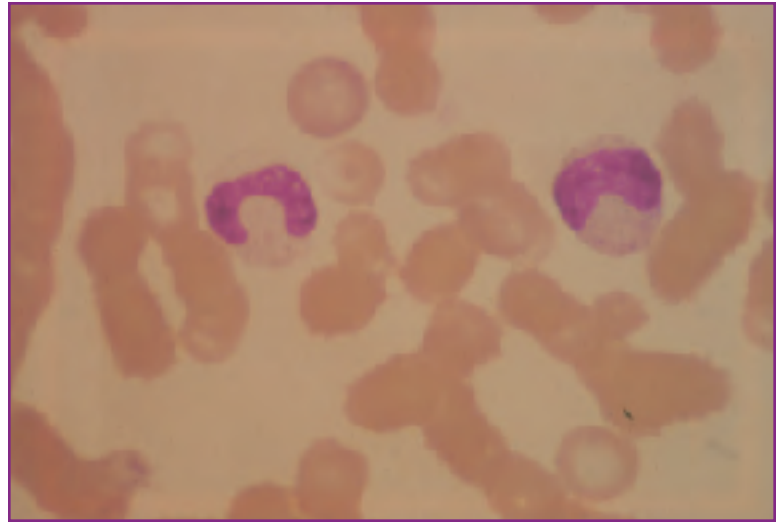
## Summary

Overall, hematologic findings suggest a severe acute inflammatory condition with superimposed stress, tissue necrosis systemic toxemia, and the anemia of inflammatory disease. Bacterial infection is suspected. The absence of thrombocytopenia suggests that despite the seriousness of the condition, DIC is not present.

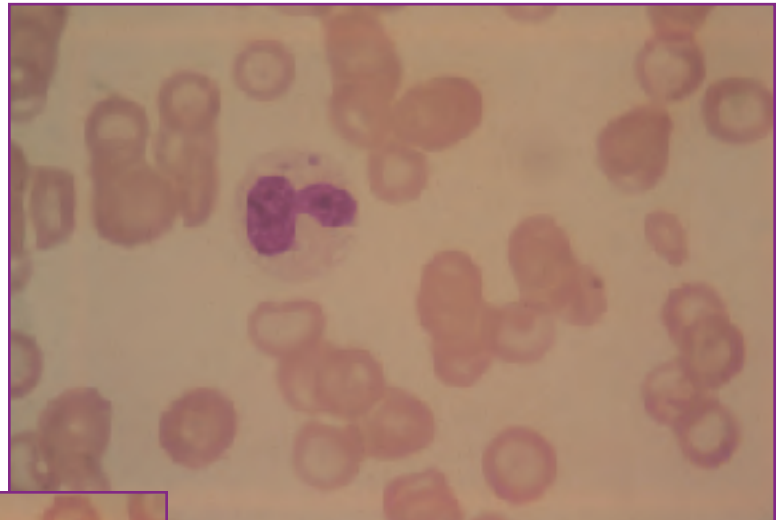
The actual diagnosis in the case was *E. coli* pyometra.



**Fig. 2** Two band cells and a mature neutrophil.



**Fig. 3** A toxic band (left), and a toxic metamyelocyte (right). The cytoplasm of both cells is too blue.



**Fig. 4** A toxic neutrophil with foamy, basophilic cytoplasm and Döhle bodies.

## CASE 5

**Signalment:** Four-year-old intact female Irish Setter

**History:** Weight loss and distended abdomen

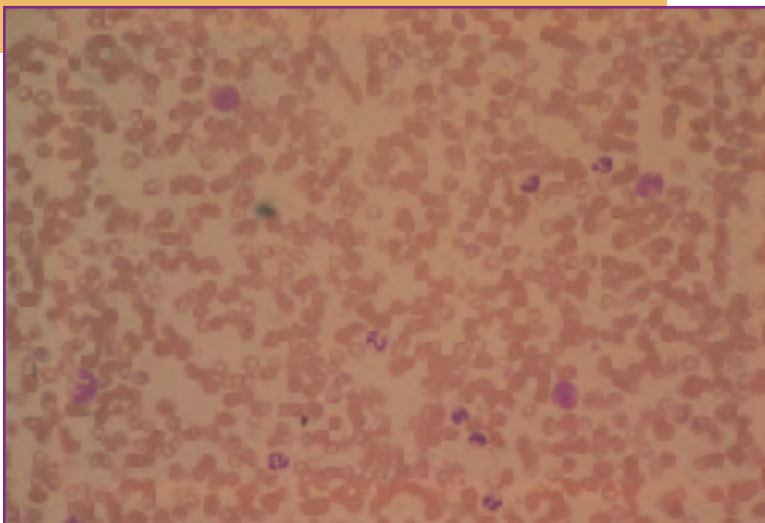
HCT	25%	WBC	17,500/ $\mu$ l
Hb	8.0 g/dl	Neutrophils	10,000/ $\mu$ l
RBC	4 x 10 <sup>6</sup> / $\mu$ l	Lymphocytes	3,000/ $\mu$ l
TP	8.2 g/dl	Monocytes	4,500/ $\mu$ l
Platelets	Adequate		

### Description

**Leukogram:** Total white cell count is normal. However, there is a marked monocytosis.

**Erythrogram:** There is a moderate normocytic (MCV = 62 fl) normochromic (MCHC = 33%) anemia with no evidence of polychromasia.

**Thrombogram:** Unremarkable.



**Fig. 5** On scanning magnification, a monocytosis is obvious. Four monocytes and seven neutrophils.

## Interpretation

1.) Inflammatory leukogram. Although the total white cell count is normal, the marked monocytosis is a clear indicator of inflammation and tissue necrosis. There is no evidence of superimposed stress. When considered in its entirety, the leukogram indicates chronic inflammation with the establishment of a new steady state between marrow production of leukocytes on the one hand and tissue consumption of leukocytes on the other.

2.) Non-regenerative anemia. Normocytic, normochromic anemias without polychromasia are nonregenerative. Pathogenesis of the anemia in this patient is probably complex. Certainly the depression of red cell production by inflammatory disease is a major contributing factor. However, the degree of anemia is too severe to be explained on the basis of inflammation alone. A potential source of blood loss should also be sought.

3.) Normal platelet numbers. Normal platelet numbers in the face of chronic inflammation is a positive finding in that it indicates the absence of DIC.

4.) Hyperproteinemia. Hyperproteinemia reflects hemoconcentration and/or increased antibody (immunoglobulin) production. In this patient, given the presence of a chronic inflammatory leukogram, antigenic stimulation with increased immunoglobulin production is almost a certainty. This can be confirmed by noting increased globulins as compared to albumin in the serum chemistry data.

## Summary

Hematologic findings are most supportive of a chronic inflammatory process with tissue necrosis, antigenic stimulation, and the anemia associated with inflammation. A second factor exacerbating the anemia is also suspected since the degree of anemia is more than inflammatory processes alone usually cause.

The actual diagnosis in this case was *E. coli* pyometra.

## CASE 6

**Signalment:** Five-year-old female mixed-breed dog

**History:** Presented in state of near collapse and extreme depression

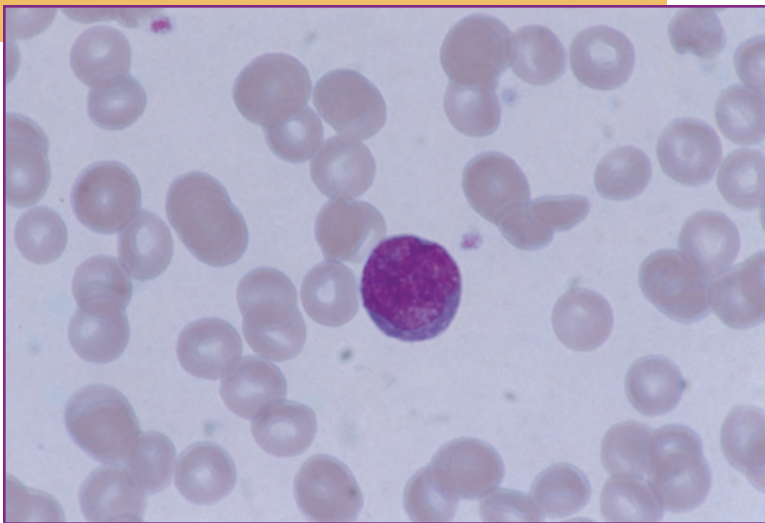
HCT	50%	WBC	5,500/ $\mu$ l
Hb	16.1 g/dl	Bands	1,100/ $\mu$ l
RBC	$7.2 \times 10^6$ / $\mu$ l	Neutrophils	2,000/ $\mu$ l
TP	8.5 g/dl	Lymphocytes	900/ $\mu$ l
Platelets	Reduced	Monocytes	1,500/ $\mu$ l

### Description

**Leukogram:** There is a leukopenia characterized by neutropenia with a left shift, lymphopenia, and a marginal monocytosis.

**Erythrogram:** There is polycythemia with hyperproteinemia.

**Thrombogram:** Thrombocytopenia.



**Fig. 6** A reactive lymphocyte with large nucleus, lacy chromatin pattern with nucleolar whorls, and basophilic cytoplasm.

## Interpretation

1.) Overwhelming inflammation. Left shift and monocytosis indicate inflammation with tissue necrosis. The presence of the left shift in the face of marked neutropenia indicates that marrow production and release of neutrophils is unable to keep up with tissue demand (overwhelming inflammation). This is an unfavorable finding in the dog or cat and suggests an emergency condition. Overwhelming inflammation is almost always an acute phenomenon.

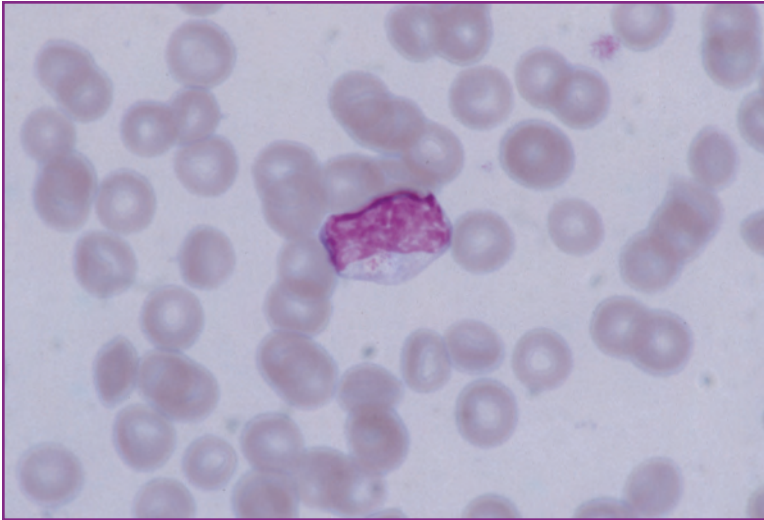
2.) Stress leukogram. Absolute lymphopenia with lymphocyte counts in the range of 700/ $\mu$ l to 1500/ $\mu$ l is most commonly associated with high levels of circulating glucocorticoids (stress).

3.) Relative polycythemia. The combination of polycythemia and hyperproteinemia suggests relative polycythemia due to dehydration and hemoconcentration. Leukogram data is not affected by hemoconcentration.

However, other tests in the laboratory profile are also affected by dehydration and can be used to support the interpretation of relative polycythemia. BUN, creatinine, and electrolytes all will elevate in the face of dehydration. If the kidneys are working, urine specific gravity will be concentrated. Hyperproteinemia in dehydration will be associated with elevations in both albumin and globulin levels. (The other cause of hyperproteinemia, antigenic stimulation, is associated with a relatively greater elevation in globulins than albumin.) In this patient, considering the inflammatory nature of the disease, antigenic stimulation may also be contributing to the hyperproteinemia.

4.) Possible DIC. Thrombocytopenia in the face of inflammation, particularly severe and overwhelming inflammation, is suggestive of possible DIC. This is a potentially life-threatening syndrome and should be confirmed by evaluating a

*Continued*



**Fig. 7** A reactive lymphocyte with abundant cytoplasm and small azurophilic granules.

complete DIC panel comprised of platelet count, prothrombin time, activated partial thromboplastin time, activated partial thromboplastin time, fibrinogen levels and fibrin split products. If three of the five tests in the panel are abnormal, DIC is considered to be present.

## Summary

Overwhelming inflammation with tissue necrosis and superimposed stress; relative polycythemia; possible DIC. This patient is in an emergency state requiring immediate attention.

The actual diagnosis in this animal was *E. coli* pyometra.

## Discussion of Cases 4, 5, and 6

When considered in aggregate, Cases 4, 5, and 6 illustrate several principles of hemogram interpretation, in particular leukogram interpretation. First, these cases clearly illustrate that inflammatory processes can present with high, low, or normal total white cell counts. In fact, the primary value of total leukocyte counts in inflammatory processes is that they provide some indication of how well the patient is coping with the inflammation. If the white cell count is elevated, then marrow production and release of leukocytes is exceeding tissue consumption. This is a favorable finding for the patient, and accordingly, left shifts with elevated neutrophil counts have been termed regenerative left shifts. In contrast, low white cell counts in inflammatory disorders indicate that tissue utilization of leukocytes exceeds marrow production and release. This is an unfavorable circumstance for the patient, and left shifts with low leukocyte counts are therefore termed degenerative left shifts. Cases of inflammatory disease where the total leukocyte counts are normal are usually chronic conditions where a new steady state has been reached and marrow production and release of granulocytes has had time to expand to meet tissue demand. In these cases, examination of marrow reveals marked granulocytic hyperplasia with normal to increased numbers of mature neutrophils, which accounts for the absence of a peripheral left shift.

A second major principle illustrated in cases 4, 5, and 6 is that leukogram data can be used prognostically as well as diagnostically. Case 4, an acute pyometra with a classic acute inflammatory leukogram, is the simplest case with the best prognosis for complete, uncomplicated recovery following hysterectomy. Case 5, a chronic pyometra with chronic inflammatory leukogram, also has a relatively good prognosis. However, the chronicity of the process suggests that the surgery itself may be complicated due to marked vascular proliferation. Case 6, an acute pyometra with overwhelming inflammation and possible DIC, has the worst prognosis. This case is clearly an emergency and requires immediate attention.

Finally, these three cases clearly illustrate that leukogram data cannot be used to differentiate among bacterial, viral, and toxic diseases (unless specific etiologic agents are seen on the blood film). Historically, it has been suggested that bacterial diseases cause leukocytosis while viral infections cause leukopenia. However, in these three cases, we have seen examples of a single bacterial agent associated with the full range of white cell response. Toxic and necrotizing processes can induce the same variability in white cell numbers. Leukogram data are used to differentiate between inflammatory and non-inflammatory processes, not between infectious and non-infectious processes.

## CASE 7

**Signalment:** Fourteen-year-old neutered male DSH cat  
**History:** Chronic weight loss with distended abdomen

HCT	30%	WBC	43,200/ $\mu$ l
Hb	9.5 g/dl	Neutrophils	38,000/ $\mu$ l
RBC	$5.6 \times 10^6$ / $\mu$ l	Lymphocytes	2,160/ $\mu$ l
TP	10.0 g/dl	Monocytes	2,360/ $\mu$ l
Platelets	Adequate	Eosinophils	680/ $\mu$ l

### Description

**Leukogram:** There is leukocytosis characterized by mature neutrophilia and monocytosis.

**Erythrogram:** There is marginal to no anemia but a marked hyperproteinemia is present.

**Thrombogram:** Unremarkable.

## Interpretation

1.) Chronic inflammatory leukogram. The monocytosis is a clear indicator of inflammation and tissue necrosis. The marked mature neutrophilia with no left shift suggests that the granulocytic compartment of the marrow is significantly expanded, a feature of chronicity. Chronicity is also suggested by the absence of lymphopenia.

2.) Suspected hypergammaglobulinemia. Hyperproteinemia is either the result of dehydration or hypergammaglobulinemia. In this patient, given the marked inflammatory leukogram, the most likely interpretation is hypergammaglobulinemia. Some contribution from dehydration cannot be absolutely ruled out, but the degree of hyperproteinemia is too great to be explained by dehydration alone.

## Summary

Hemogram data, when considered in conjunction with the clinical presentation and history, are consistent with a diagnosis of FIP. FIP was confirmed both serologically and at necropsy.



## CASE 8

**Signalment:** Three-year-old female Birman cat

**History:** Anorexia and dyspnea of several days' duration

HCT	25%	WBC	54,000/ $\mu$ l
Hb	8.1 g/dl	Bands	6,000/ $\mu$ l
RBC	$5.6 \times 10^6$ / $\mu$ l	Neutrophils	44,000/ $\mu$ l
TP	7.5 g/dl	Lymphocytes	1,200/ $\mu$ l
Platelets	Reduced	Monocytes	2,000/ $\mu$ l
		Eosinophils	800/ $\mu$ l

**Morphology:** There is marked toxicity of neutrophils. Occasional reactive lymphocytes are seen.

### Description

**Leukogram:** Marked leukocytosis characterized by neutrophilia with a left shift, marginal lymphopenia and monocytosis.

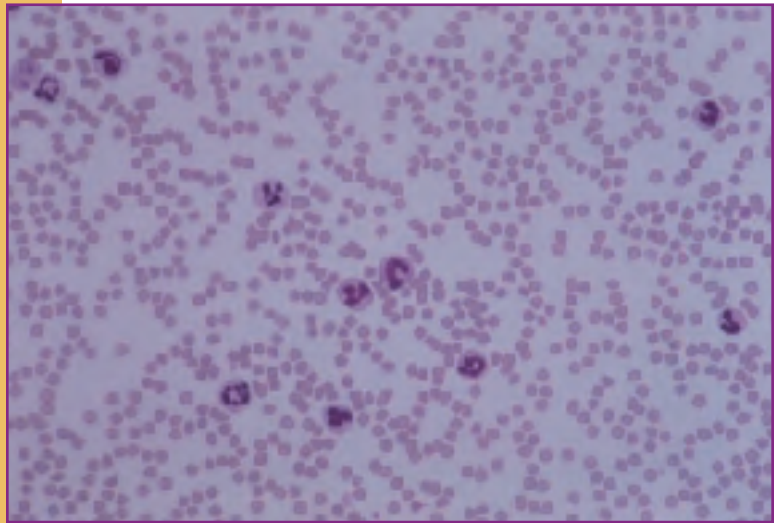
**Erythrogram:** There is a mild normocytic normochromic anemia (MCV = 43 fl, MCHC = 33%).

**Thrombogram:** Thrombocytopenia.

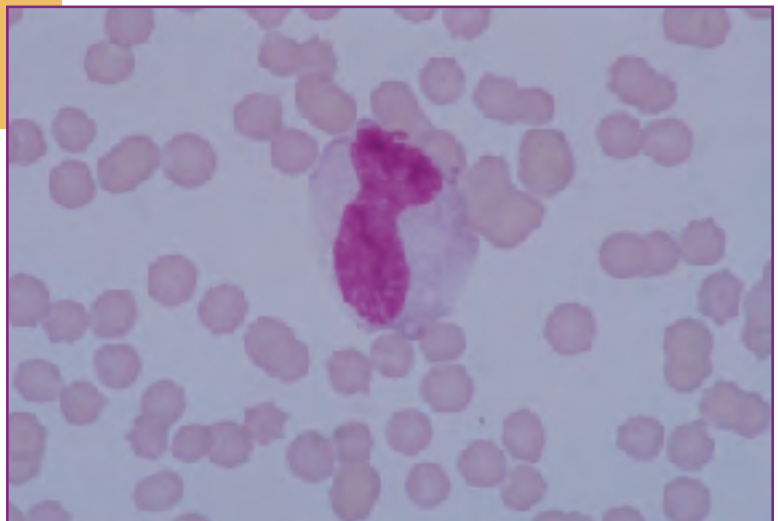
## Interpretation

1.) Active inflammatory leukogram with superimposed stress, tissue necrosis, and systemic toxemia. The left shift and monocytosis are indicative of inflammation. Monocytosis also indicates tissue necrosis. High circulating levels of glucocorticoids (stress) are indicated by the marginal lymphopenia. Systemic toxemia is indicated by the presence of toxic neutrophil on the blood film. In this case, toxicity is severe. In dogs and cats, severe systemic toxemia is most often associated with bacterial infections.

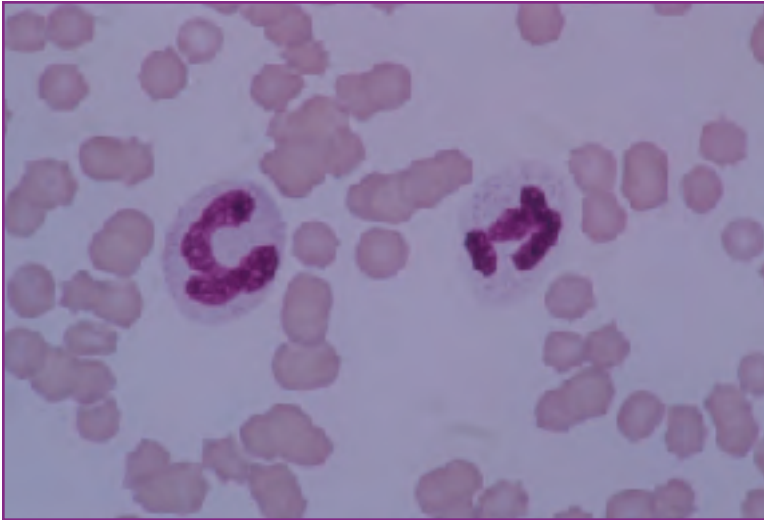2.) Anemia of inflammatory disease. Mild to moderate



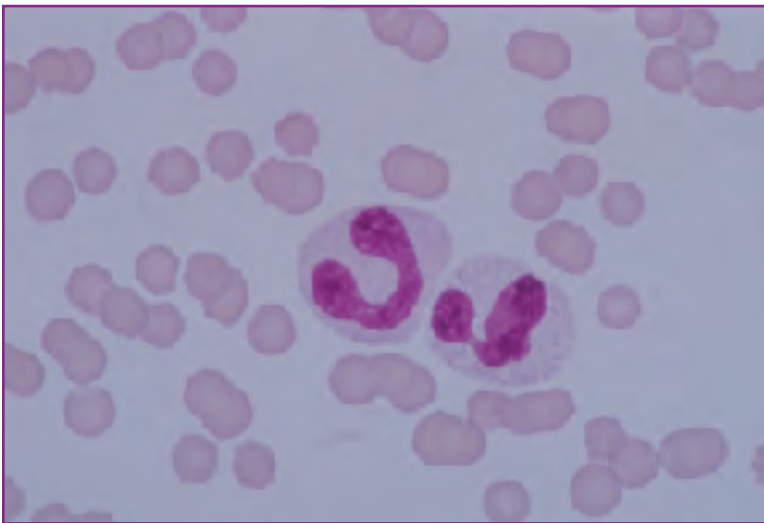
**Fig. 8** Low magnification reveals a leukocytosis with neutrophilia and left shift.



**Fig. 9** High magnification. A giant toxic band cell (center). Note the blue cytoplasm (Wright's stain x 100).



**Fig. 10** Two toxic neutrophils with foamy, basophilic cytoplasm (Wright's stain x 100).



**Fig. 11** A toxic band cell (left), and a toxic neutrophil (right). Again, note the foamy, basophilic cytoplasm (Wright's stain x 100).

normocytic, normochromic non-regenerative anemia is consistent with the anemia of inflammatory disease.

3.) Possible DIC. Considering the severity of the inflammation and systemic toxemia, the thrombocytopenia may be an indicator of DIC. A complete DIC panel is warranted.

## Summary

The diagnosis in this patient was bacterial pyothorax. Based on a positive DIC panel, sub-clinical DIC also was identified.

## CASE 9

**Signalment:** Eight-year-old female Cocker Spaniel  
**History:** Presented with generalized lymphadenopathy

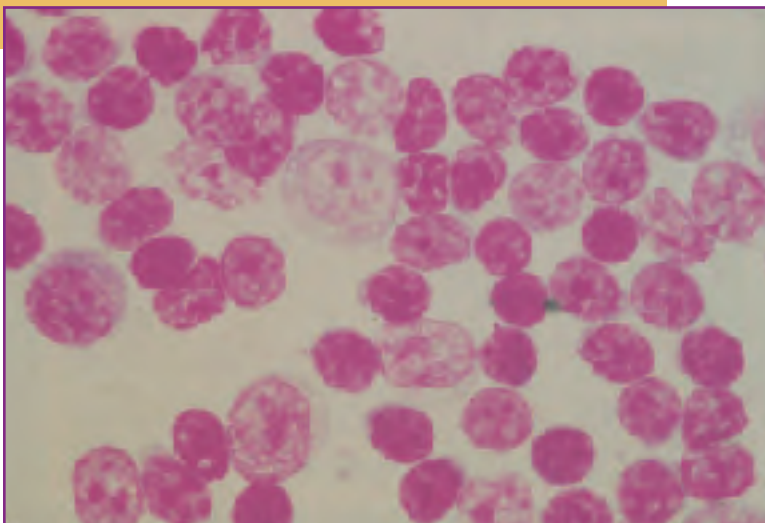
HCT	15%	WBC	5,000/ $\mu$ l
Hb	5.0 g/dl	Neutrophils	3,000/ $\mu$ l
RBC	$2.6 \times 10^6$ / $\mu$ l	Lymphocytes	700/ $\mu$ l
TP	6.0 g/dl	Monocytes	1,000/ $\mu$ l
Platelets	Reduced	Eosinophils	300/ $\mu$ l

### Description

**Leukogram:** There is leukopenia characterized by neutropenia and lymphopenia. No white cell morphologic abnormalities are noted on the peripheral blood film.

**Erythrogram:** There is marked normocytic normochromic anemia with no evidence of polychromasia.

**Thrombogram:** Thrombocytopenia.



**Fig. 12** Aspirate of a normal lymph node. Normal small lymphocytes predominate with several larger prolymphocytes.

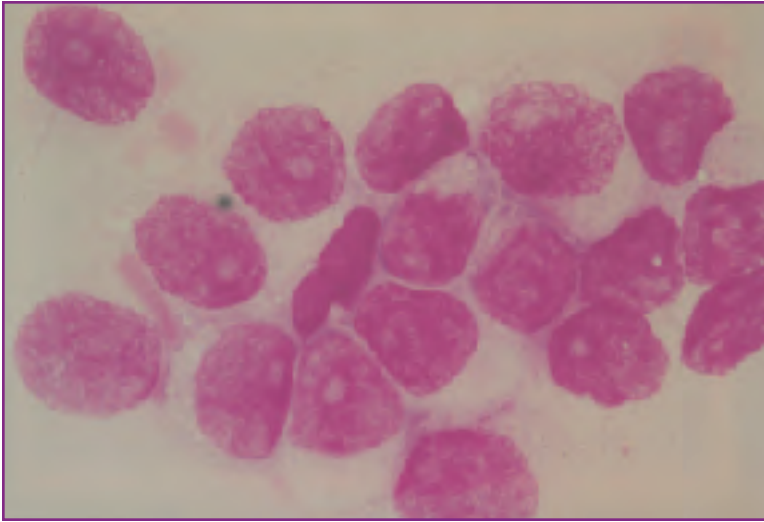
## Interpretation

Possible marrow disease. Leukogram, erythrogram, and thrombogram data, considered collectively, indicate pancytopenia. Unexplained cytopenias of one or more marrow cell line suggests a possible marrow production problem. Bone marrow examination is required for further evaluation. Possibilities include marrow hypoplasia/aplasia, myelophthitic syndrome, and myelofibrosis. In this case, marrow aspirates were highly cellular but abnormal. Few granulocyte, red cell, and platelet precursors were present. Instead, the predominant cell seen was a large round cell with a scant to moderate rim of faintly basophilic cytoplasm. The nuclei were round with a lacy reticular pattern and very large prominent singular pale blue nucleoli. The diagnosis was myelophthitic syndrome due to lymphoblastic lymphosarcoma.

## Discussion

Case #9 was originally submitted by the referring veterinarian as suspect lymphosarcoma; blood was collected in an attempt to confirm the diagnosis. It should be noted that where there is generalized lymphadenopathy, the preferred sample is a lymph node biopsy. Only rarely can a diagnosis of lymphosarcoma be confirmed with a CBC. In fact, the most common hematologic finding in cases of lymphosarcoma is profound non-regenerative anemia, which occurs when the marrow has been infiltrated by malignant lymphoblasts. Lymphopenia and lymphocytosis occur far less frequently. Lymphopenia results when normal recirculating lymphocytes become trapped in massively enlarged lymph nodes and cannot re-enter the peripheral blood. Lymphocytosis only

*Continued*



**Fig. 13** Aspirate of a lymph node with lymphoma. The majority of the cells are large blasts with very large nuclei and prominent nucleoli.

occurs when the marrow is so infiltrated that malignant cells spill over in high numbers into the peripheral blood. Lymphocytosis with malignant cells in circulation is, therefore, a late finding in most cases of lymphosarcoma even though it is the only circumstance where the diagnosis can be confirmed with the CBC alone.

## CASE 10

**Signalment:** Six-year-old female DSH cat

**History:** Sudden onset dyspnea of approximately 2 days' duration

HCT	45%	WBC	10,600/ $\mu$ l
Hb	15.0 g/dl	Neutrophils	10,000/ $\mu$ l
RBC	$9.0 \times 10^6$ / $\mu$ l	Lymphocytes	200/ $\mu$ l
TP	4.1 g/dl	Eosinophils	400/ $\mu$ l
Platelets	Adequate		

### Description

**Leukogram:** The only abnormality noted in the leukogram is profound lymphopenia.

**Erythrogram:** Red cell parameters fall within the reference range. However, hypoproteinemia is present.

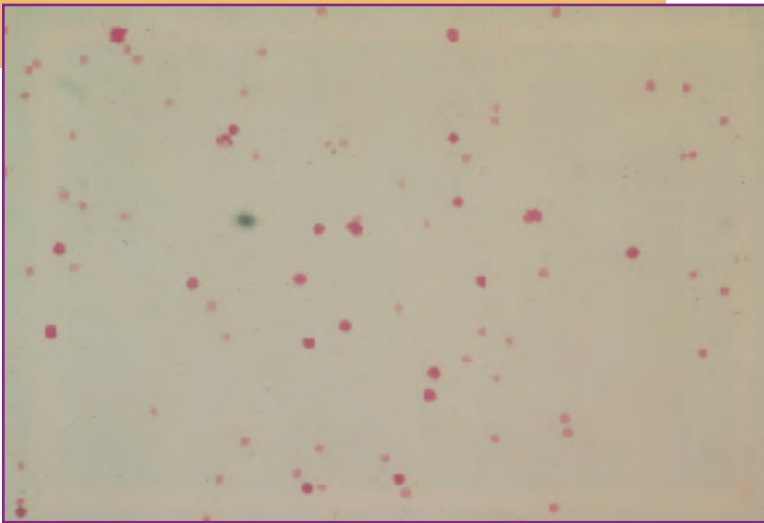
**Thrombogram:** No abnormalities noted.

## Interpretation

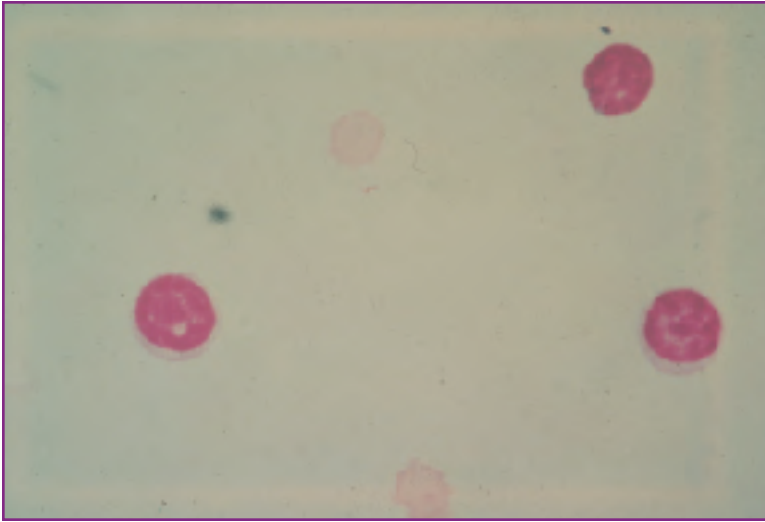
1.) Profound lymphopenia. The most common cause of lymphopenia is high circulating glucocorticoid levels (stress leukogram). However, elevated glucocorticoids generally cause lymphopenias in the range of 700/ $\mu$ l to 1500/ $\mu$ l. When lymphocyte counts drop below 700/ $\mu$ l, other cases of lymphopenia should be considered. Profound lymphopenias can be caused by anything that interrupts the normal circulatory pattern of lymphocytes. Lymphocytes are predominantly long-lived cells, which circulate in peripheral blood to lymph nodes, migrate through the lymph nodes and enter the efferent lymphatics, and travel via lymph to re-enter the blood via the thoracic duct. Causes of profound lymphopenias are therefore primarily lymphatic obstruction (neoplasias), and lymphatic rupture (chylothorax, chyloperitoneum). With the history of sudden onset dyspnea, chylothorax should be strongly considered in this patient.

2.) Hypoproteinemia. Hypoproteinemia can result from loss of blood or lymph, protein losing enteropathy, protein-

*Continued*



**Fig. 14** Low magnification of pleural fluid. Normal small lymphocytes predominate. Red cells are seen in the background. This is typical of a chylous effusion.



**Fig. 15** High magnification of Fig. 14. Normal small lymphocytes.

losing nephropathy or lack of protein production by a damaged liver. In this case, the combination of profound lymphopenia, hypoproteinemia, and clinical dyspnea all indicate an underlying chylous effusion.

### **Summary**

The diagnosis of chylous effusion (chylothorax) was confirmed cytologically by evaluation of excessive pleural fluid.

## CASE 11

**Signalment:** Eight-week-old male Beagle

**History:** Sudden onset of respiratory distress and diarrhea (dark feces) of 2 days' duration

HCT	25%	WBC	19,100/ $\mu$ l
Hb	8.1 g/dl	Bands	1,100/ $\mu$ l
RBC	4.0 x 10 <sup>6</sup> / $\mu$ l	Neutrophils	14,000/ $\mu$ l
TP	4.5 g/dl	Lymphocytes	1,000/ $\mu$ l
Platelets	Normal numbers, some large	Eosinophils	3,000/ $\mu$ l

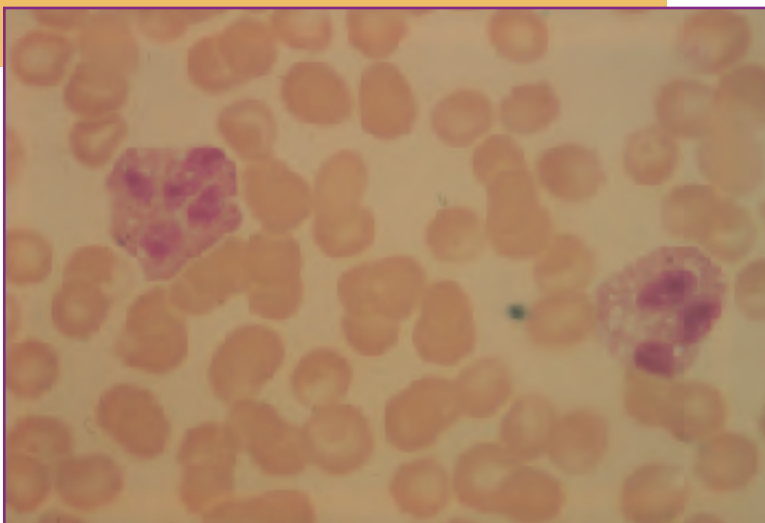
**Morphology:** Mild to moderate polychromasia

### Description

**Leukogram:** There is a leukocytosis (mild) with a mild neutrophilia and left shift, eosinophilia, and lymphopenia.

**Erythrogram:** There is a moderate anemia with mild to moderate polychromasia. There is mild to moderate hypoproteinemia.

**Thrombogram:** Unremarkable.



**Fig. 16** Two normal eosinophils.

## Interpretation

1.) Acute inflammatory leukogram with systemic hypersensitivity and superimposed stress. Indicators of inflammation are the left shift and eosinophilia. The eosinophilia also is an indicator of systemic hypersensitivity. Considering the age of the patient, the possibility of circulating larvae of intestinal parasites (hookworms, ascarids) as a cause of the hypersensitivity should be investigated. An associated regenerative anemia suggesting blood loss would be supportive evidence of parasitemia. Even in the absence of hookworm ova in the feces, late stage larvae in the gut are capable of causing blood loss before ova are produced. The marginal lymphopenia in this patient is best interpreted as indicative of high circulating levels of glucocorticoids (stress).

2.) Regenerative anemia. A mild to moderate anemia accompanied by mild to moderate polychromasia is suggestive of a regenerative anemia. An absolute reticulocyte count would probably be useful in confirming this interpretation. Regenerative anemias are the result of either blood loss or hemolysis. Considering the suspicion of intestinal parasitism and the findings on the leukogram, blood loss anemia is the most likely cause.

3.) Hypoproteinemia. Young dogs (less than 9 months to 1 year) generally have lower total protein levels than adults have (in the range of 5.0 g/dl to 6.0 g/dl) but the level here is quite low and is a clear hypoproteinemia. Hypoproteinemia can result from loss of blood or lymph, protein losing nephropathy (confirmed by protein loss in urine), protein losing enteropathy (associated with diarrhea with voluminous stools), or lack of protein (albumin) production by the liver (confirmed by other evidence of liver pathology). In this case the likely cause is blood loss as a result of intestinal parasitism.

## Summary

Considered collectively, hematologic data suggests severe hookworm infection with associated blood loss anemia and hypoproteinemia. Leukogram data suggests that there are still systemically migrating larvae on their way to the gut causing a hypersensitivity reaction and inflammation.

## CASE 12

**Signalment:** Nine-week-old female  
Beagle

**History:** Diarrhea and listlessness  
of several weeks' duration

HCT	15%	WBC	17,000/ $\mu$ l
Hb	5.6 g/dl	Neutrophils	10,000/ $\mu$ l
RBC	$2.7 \times 10^6$ / $\mu$ l	Lymphocytes	2,000/ $\mu$ l
TP	4.5 g/dl	Monocytes	2,500/ $\mu$ l
NRBC	30/100 WBC	Eosinophils	2,500/ $\mu$ l
Platelets	Adequate		

**Morphology:** Mild to moderate polychromasia, many NRBC, some mitotic.

### Description

**Leukogram:** There is a normal leukocyte count characterized by a marked eosinophilia and monocytosis.

**Erythrogram:** There is a marked anemia with an inappropriate nucleated red cell response (too many nucleated RBCs relative to the degree of polychromasia). There is also moderate hyperproteinemia.

**Thrombogram:** Unremarkable.

## Interpretation

1.) Inflammatory leukogram with tissue necrosis and systemic hypersensitivity. Monocytosis and eosinophilia are clear indicators of inflammation even though total white cell count is in the reference range. Furthermore, monocytosis suggests demand for phagocytosis (tissue necrosis) while eosinophilia (persistent) signals a systemic hypersensitivity reaction. Considering that total leukocyte count is normal, there is no left shift, and there is no lymphopenia, the inflammation is most likely chronic. Hyperproteinemia due to hypergammaglobulinemia and the mild to moderate non-regenerative anemia of inflammation might be anticipated.

2.) Severe nonregenerative anemia with inappropriate nucleated red cell response. Mild to moderate polychromasia in the face of severe anemia is an inadequate response. Furthermore, the number of nucleated red cells present is far too high for the degree of polychromasia and the response is therefore classified as inappropriate. The notation of mitotic red cell precursors in the peripheral blood is also quite disturbing and suggests that some circulating nucleated red cells are fairly immature (rubricytes or more primitive). Inappropriate nucleated red cell responses are the result of marrow stromal damage (heavy metal toxicity, anoxia, high circulating glucocorticoids), inadequate splenic function, fractures, extramedullary hematopoiesis, or red cell marrow exhaustion. Compared to adult animals, very young animals have less marrow reserve. Considering the severity of anemia in this patient, the inappropriate nucleated response here probably results from marrow

stromal damage in the form of anoxic injury and red cell marrow exhaustion as the red cell compartment attempts to respond to the severe anemia. This is an unfavorable finding in this puppy.

## Summary

This puppy is a littermate of the puppy in Case 11, seen one week later, also untreated at the time of presentation. This puppy, like the puppy in the previous case, has severe hookworm infestation. Migrating larvae are still probably present (based on the leukogram) as are parasitic forms in the bowel. With the inability of the red cell marrow to keep pace with the loss of blood, the prognosis is guarded. Note that the inflammatory leukogram in this puppy, seen seven days after the first, is chronic and that there is no evidence of a stress leukogram (even though the puppy is undoubtedly "stressed") which suggests chronic antigenic stimulation.



## CASE 13

**Signalment:** Fourteen-week-old male Beagle

**History:** Listless, anorectic, pale mucous membranes

HCT	12%	WBC	10,000/ $\mu$ l
Hb	3.0 g/dl	Neutrophils	7,000/ $\mu$ l
RBC	$2.3 \times 10^6$ / $\mu$ l	Lymphocytes	1,000/ $\mu$ l
TP	3.8 g/dl	Monocytes	1,500/ $\mu$ l
Platelets	Increased numbers with many large platelets	Eosinophils	500/ $\mu$ l

**Morphology:** Moderate anisocytosis and poikilocytosis with moderate numbers of red cell fragments. Numerous cells have large pale centers.

### Description

**Leukogram:** Total white cell count is within normal limits, but there is a lymphopenia (marginal) and mild monocytosis.

**Erythrogram:** There is a marked microcytic hypochromic anemia ( $MCV = 12/2.3 \times 10 = 52$  fl,  $MCHC = 3/12 \times 100 = 25\%$ ). Hypochromia and microcytosis are confirmed by red cell morphology on the blood film. There is also red cell fragmentation.

**Thrombogram:** Thrombocytopenia.

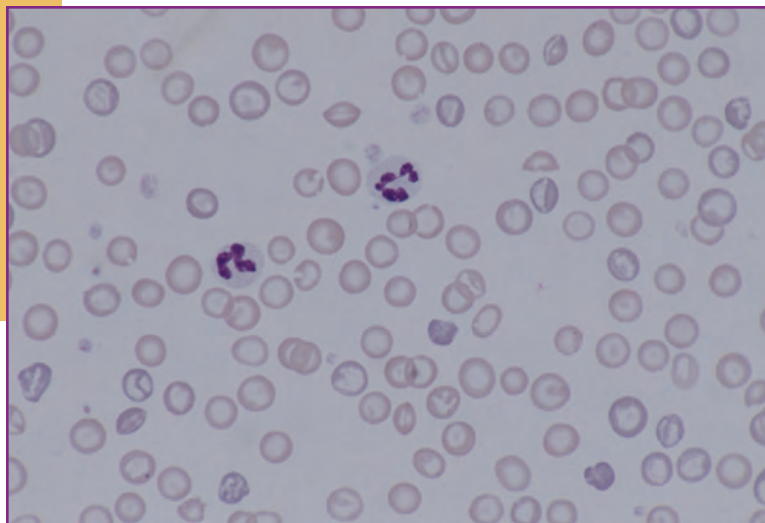
## Interpretation

1.) Inflammatory leukogram with superimposed stress and tissue necrosis. Monocytosis indicates inflammation and tissue necrosis. Marginal lymphopenia indicates superimposed stress. It is difficult to ascertain whether the process is acute or chronic. Repeat leukograms might be helpful in this regard.

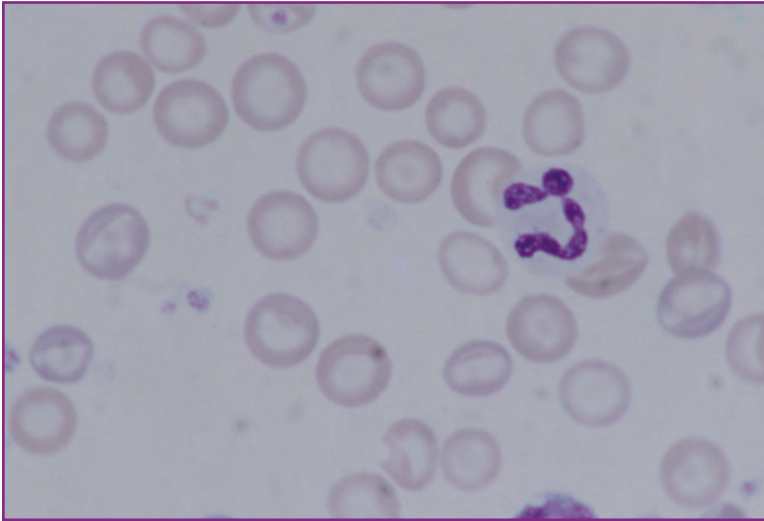
2.) Iron-deficiency anemia. Marked microcytic hypochromic anemia is highly suggestive of chronic blood loss with resultant iron deficiency. Iron is required for hemoglobin formation. In turn, red cell hemoglobinization regulates division of red cell precursors in the marrow. When iron is unavailable for adequate hemoglobin synthesis, precursors undergo additional divisions in the marrow, becoming smaller and smaller. Red cells eventually released into peripheral blood are both small (microcytic) and deficient in hemoglobin (hypochromic). Although the mechanism is not clearly understood, hypochromic red cells are also more fragile than normal, hence the increased numbers of red cell fragments on the blood film.

3.) Reactive thrombocytopenia. With the severity of the anemia, it is likely that circulating levels of the red cell growth factor erythropoietin are quite high. Erythropoietin stimulates both red cell production and platelet production. The thrombocytopenia with megaplatelets (immature platelets) is therefore most likely a reactive thrombo-

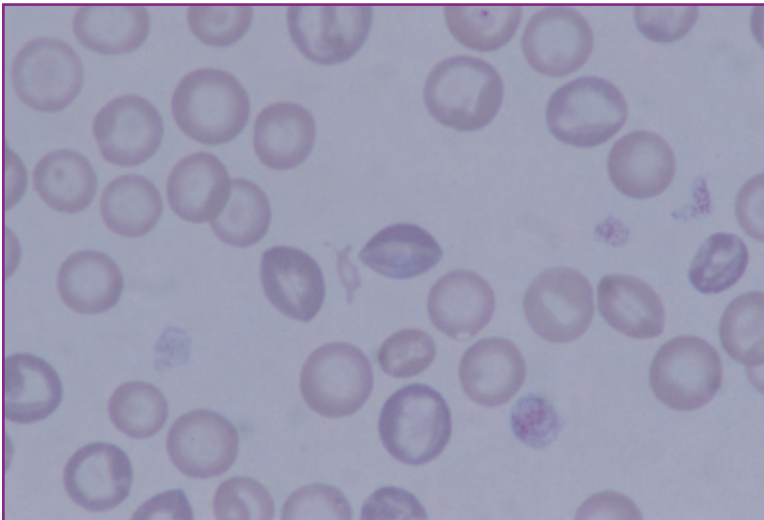
*Continued*



**Fig. 17** Scanning magnification. Note the large unstained areas of central pallor in the red cells.



**Fig. 18** High magnification. The marked central pallor of the red cells typical of iron deficiency is easily apparent. A red cell fragment (schizocyte) is at left center.



**Fig. 19** High magnification. A schizocyte is at center. Several polychromatophils are also present.

cythemia in response to the erythropoietin. The anemia is non-regenerative (note minimal polychromasia) because the iron-deficient marrow is unable to respond. White cell production is not affected by erythropoietin.

## Summary

This pup is from the same litter as Cases 11 and 12. Like the others, it was untreated at the time of presentation. The primary diagnosis is severe hookworm infestation with iron deficiency anemia resulting from chronic blood loss.

## CASE 14

**Signalment:** One-year-old male Siamese cat

**History:** Sudden onset depression and anorexia with pale, icteric mucous membranes

HCT	20%	WBC	18,700/l
Hb	6.4 g/dl	Bands	1,000/l
RBC	$3.7 \times 10^6/l$	Neutrophils	15,000/l
TP	6.5 g/dl	Lymphocytes	1,200/l
Platelets	Adequate	Monocytes	1,500/l

**Morphology:** Minimal polychromasia is present. Numerous RBCs contain chains of small basophilic bodies or ring forms.

### Description

**Leukogram:** There is mild leukocytosis with neutrophilia, left shift, monocytosis, and a marginal lymphopenia.

**Erythrogram:** There is a moderate normocytic normochromic anemia. (MCV = 54 fl, MCHC = 32%). The basophilic bodies on the red cells are consistent with *Hemobartonella felis*.

**Thrombogram:** Unremarkable.

## Interpretation

1.) Active inflammatory leukogram with tissue necrosis and superimposed stress. Indicators of inflammation are the left shift and the monocytosis. Monocytosis is also an indicator of tissue necrosis. The marginal lymphopenia is indicative of superimposed stress.

2.) Anemia due to hemobartonellosis. The presence of large numbers of *Hemobartonella* bodies on the blood film establishes the diagnosis of hemobartonellosis. In its primary form, hemobartonellosis is a regenerative hemolytic anemia. In this case, there is no evidence of regeneration (no polychromasia) at the time of presentation. Hemobartonellosis may also be seen as a non-regenerative anemia when it occurs secondarily to serious immunosuppressive disorders such as FeLV, FIV, or FIP. Primary hemobartonellosis responds well to antibiotic therapy; however, when hemobartonellosis occurs secondarily, the prognosis is guarded. Clearly, this patient should be monitored over the next few days for the appearance of polychromasia and reticulocytosis. Tests for FeLV, FIV, and FIP are warranted. The inflammatory leukogram in this case is probably in response to the destruction of infected

*Continued*

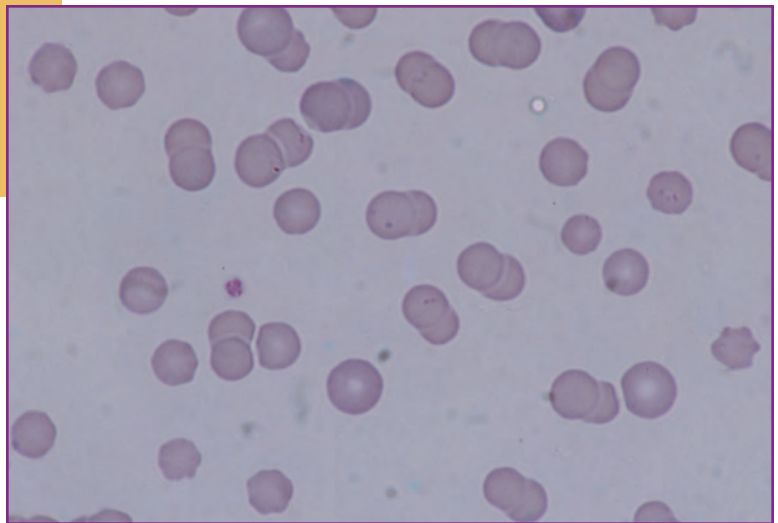


Fig. 20-22 Numerous red cells parasitized by *Hemobartonella felis* are seen in the three figures. Organisms are present singly and in chains. (Wright's stain x 100).

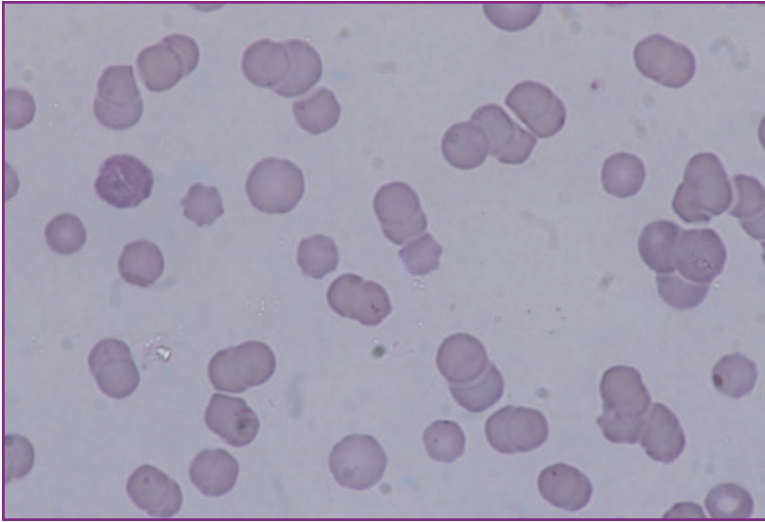


Fig. 21

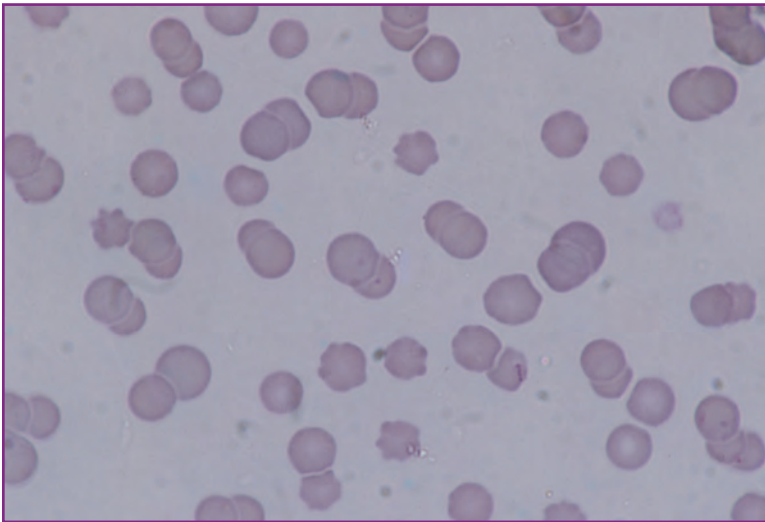


Fig. 22

red blood cells by tissue macrophages. Red cell destruction is a form of tissue necrosis.

### Summary

Polychromasia/reticulocytosis became prominent within 24 to 48 hours after initial presentation. Over the same period, the number of cells containing *Hemobartonella* bodies dropped dramatically as infected cells were removed from the blood. Tests for FeLV, FIV, and FIP were negative. The anemia responded favorably to tetracycline therapy. Clearly, this was a case of primary hemobartonellosis, which presented in the first few days of infection before a fully developed regenerative response was apparent.

## CASE 15

**Signalment:** Five-year-old female Basset Hound

**History:** Sudden onset lethargy, emesis, anorexia, and yellow mucous membranes of approximately 4 days' duration

HCT	25%	WBC	19,500/ $\mu$ l
Hb	7.0 g/dl	Bands	2,000/ $\mu$ l
RBC	$3.0 \times 10^6$ / $\mu$ l	Neutrophils	15,000/ $\mu$ l
TP	7.0 g/dl	Lymphocytes	1,200/ $\mu$ l
Platelet	Adequate	Monocytes	1,300/ $\mu$ l

**Morphology:** Moderate to marked polychromasia, numerous schizocytes, and spherocytes.

### Description

**Leukogram:** There is a mild leukocytosis with neutrophilia, left shift, marginal monocytosis, and marginal lymphopenia.

**Erythrogram:** There was moderate anemia characterized by polychromasia, schizocytes and spherocytosis.

**Thrombogram:** Unremarkable.

## Interpretation

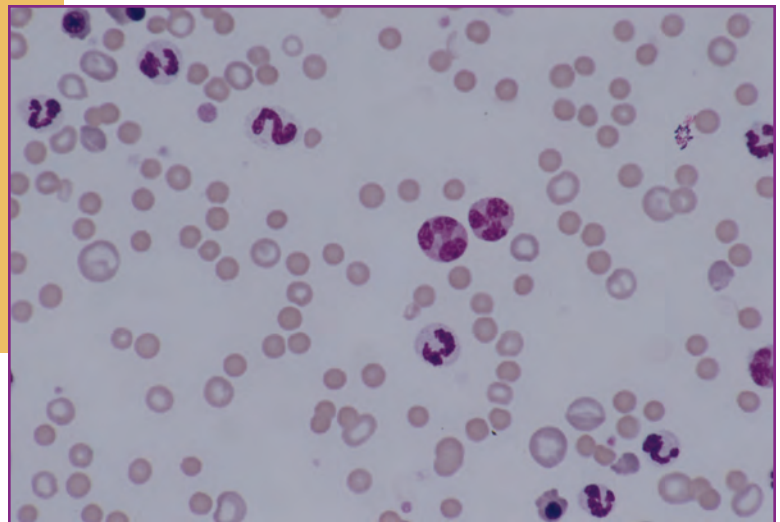
1.) Inflammatory leukogram with tissue necrosis and superimposed stress. The left shift and marginal monocytosis are indicators of inflammation. Marginal monocytosis also indicates tissue necrosis. The marginal lymphopenia strongly suggests superimposed stress.

2.) Suspected immune-mediated hemolytic anemia. Anemia with moderate to marked polychromasia implies a regenerative anemia. Regenerative anemias are either the result of hemolysis or blood loss. In this case, the presence of spherocytes on the peripheral blood film strongly suggests an immune-mediated hemolytic process. A direct antiglobulin test (Coomb's test, DAT) could be run for confirmation.

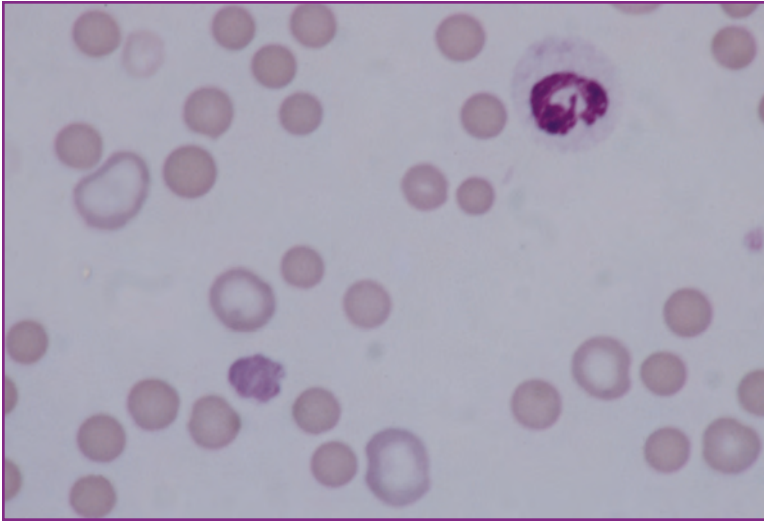
## Comment

Immune-mediated hemolytic anemias are often accompanied by inflammatory leukograms with tissue necrosis. The source of the tissue necrosis is the breakdown of red blood cells both in the circulation and in tissues rich in

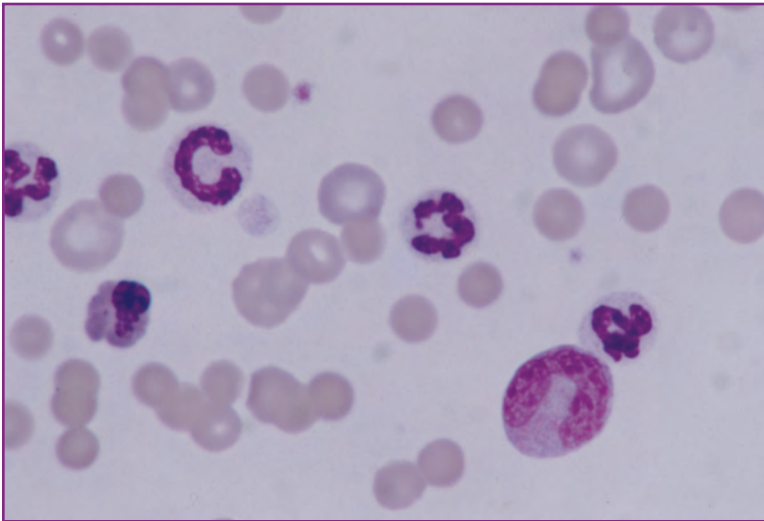
*Continued*



**Fig. 23** Scanning magnification. Red cells exhibit anisocytosis. Several polychromatophils and nucleated red cells are present. Leukocytes include two monocytes (at center), several mature neutrophils, and a band cell (top left center).



**Fig. 24-25 High magnification. Note the presence of spherocytes, several polychromatophils and a nucleated red (Fig. 5.25). Red cell changes are consistent with immune-mediated hemolytic anemia. White cells present include a monocyte (Fig. 5.25), a band cell (Fig. 5.25), and mature neutrophils. The neutrophil in Fig. 5.25 is slightly toxic.**



**Fig. 25**

macrophages such as spleen. The adequate platelet count is a favorable finding in this patient; some cases of immune-mediated hemolysis are also accompanied by immune-mediated thrombocytopenia. Patients with both hemolysis and thrombocytopenia are generally less responsive to therapy than immune-mediated hemolysis alone.

## CASE 16

**Signalment:** Eight-year-old female  
German Shepherd

**History:** Chronic wasting syndrome

HCT	30%	WBC	15,350/ $\mu$ l
Hb	9.0 g/dl	Neutrophils	8,000/ $\mu$ l
RBC	4.0 x 10 <sup>6</sup> / $\mu$ l	Lymphocytes	3,000/ $\mu$ l
TP	6.5 g/dl	Monocytes	4,000/ $\mu$ l
Platelets	Adequate	Eosinophils	350/ $\mu$ l

Reticulocyte count = 5 %

### Description

**Leukogram:** There is a marked monocytosis; all other values are within the reference range.

**Erythrogram:** There is a mild marginally macrocytic (calculated MCV = 75 fl) marginally hypochromic (calculated MCHC = 30%) anemia with an absolute reticulocyte count of approximately 200,000/ $\mu$ l (reference range to 80,000/ $\mu$ l). Spiculated poikilocytosis is prominent.

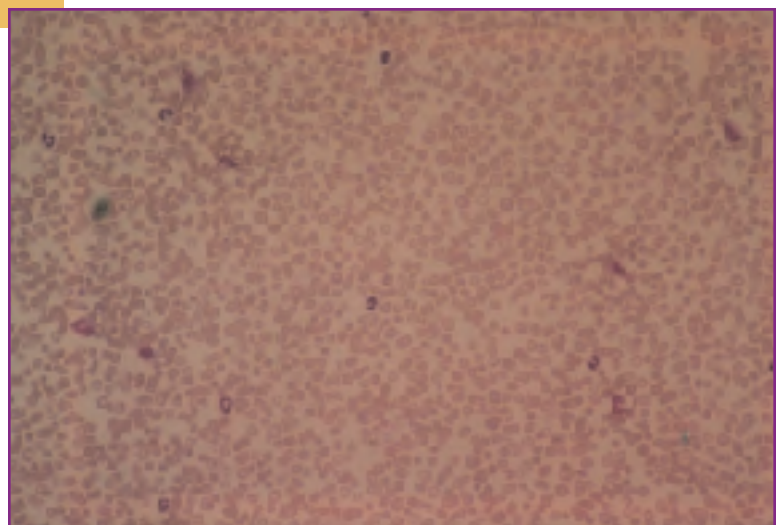
**Thrombogram:** Unremarkable.

### Interpretation

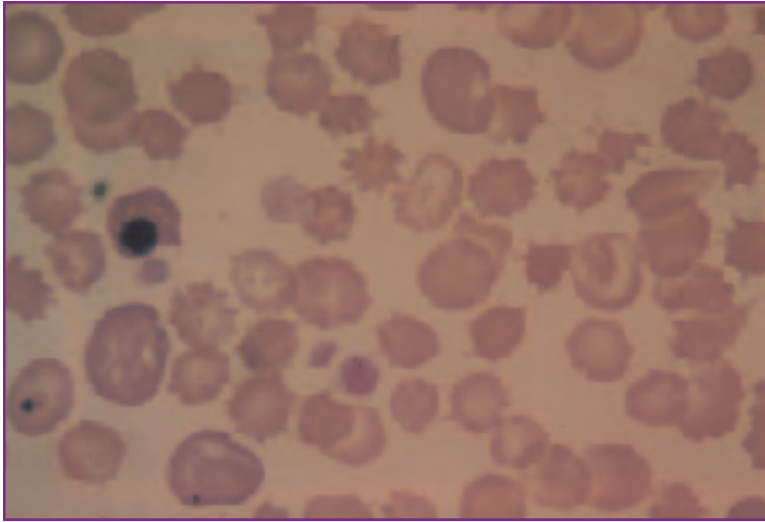
1.) Chronic inflammatory leukogram with tissue necrosis. Monocytosis is an indicator of both inflammation and tissue necrosis. The normal total leukocyte count, absence of a neutrophilia and left shift, and absence of lymphopenia, all suggest the establishment of a new white cell steady state with marrow production of leukocytes balancing tissue demand (utilization). There is probably granulocytic hyperplasia in the marrow and shortened circulating half-life of granulocytes in the peripheral blood. These are classic features of chronic inflammation. With the presence of a chronic inflammatory leukogram, several other hemogram changes might be anticipated. The mild to moderate non-regenerative anemia associated with inflammatory disease is to be expected. Furthermore, chronic inflammation is often associated with hyperproteinemia as a result of hypergammaglobulinemia.

2.) Regenerative acanthocytic anemia. Anemia with polychromasia and reticulocytosis is regenerative. Consequently, the anemia in this case cannot be explained as the anemia of inflammatory disease alone. Regenerative anemias result from either blood loss or hemolysis. Acanthocytes are red cells with 2 to 10 blunt, glove-like projections from the surface. Acanthocytic anemia in dogs has been associated with liver disease. In particular, acanthocytic regenerative anemia has been associated with

*Continued*



**Fig. 26** Scanning magnification. Monocytosis is apparent. Red cells exhibit anisocytosis and polychromasia.



**Fig. 27** High magnification. Two polychromatophils and nucleated red cells (left). Numerous red cells have multiple finger-like projections (acanthocytes). Platelets are obvious.

bleeding hemangiosarcomas of the liver, especially in middle-aged, large breed dogs such as the German Shepherd patient in this case. A possibility of abdominal hemangiosarcoma should therefore be strongly considered here. The finding of adequate platelets is significant and favorable. Many cases of abdominal hemangiosarcomas present either with disseminated or localized coagulopathies; these are generally thrombocytopenic.

### Summary

Radiography revealed an enlarged spleen and liver. At exploratory laparotomy, multiple neoplastic nodules were found in both organs. Histopathology confirmed the preliminary diagnosis of hemangiosarcoma. Many of the nodules appeared to have necrotic centers; tumor necrosis was the presumed cause of the inflammatory leukogram.



## CASE 17

**Signalment:** Fifteen-year-old neutered female DSH cat

**History:** Weight loss, pica, and hyperexcitability

HCT	35%	WBC	11,000/ $\mu$ l
Hb	12.0 g/dl	Neutrophils	8,500/ $\mu$ l
RBC	$7.5 \times 10^6$ / $\mu$ l	Lymphocytes	1,700/ $\mu$ l
TP	6.5 g/dl	Monocytes	500/ $\mu$ l
Platelets	Adequate	Eosinophils	300/ $\mu$ l

**Morphology:** 50% or more of the red cells contain discernible Heinz bodies.

### Description

**Leukogram:** Unremarkable

**Erythrogram:** Numerical data are unremarkable; however, the presence of large numbers of Heinz bodies on the blood film is noteworthy.

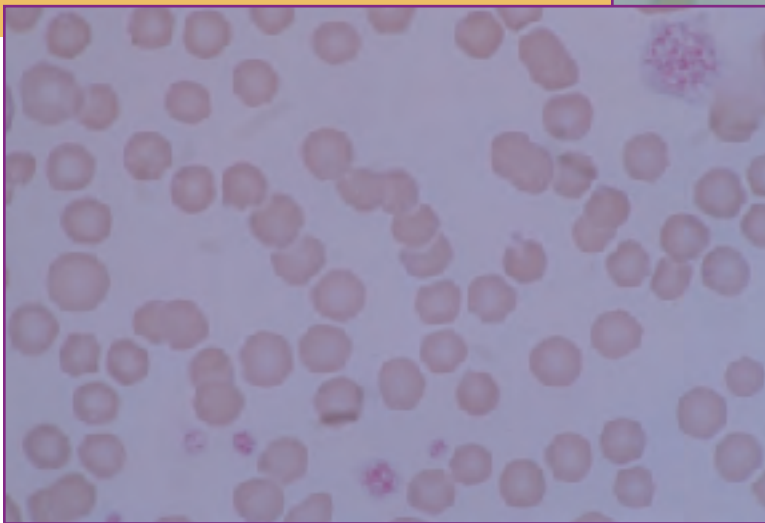
**Thrombogram:** Unremarkable.

## Interpretation

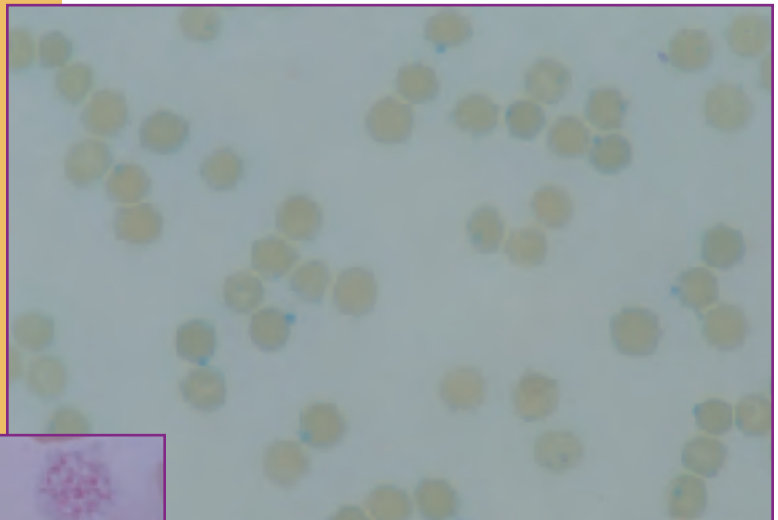
Possible metabolic disease. In cats, the presence of large numbers of Heinz bodies in the absence of hemolytic anemia has been associated with metabolic and endocrinologic diseases. The most frequent associations have been with diabetes mellitus, hyperthyroidism, and liver disease.

## Summary

Further evaluation of this patient led to a diagnosis of hyperthyroidism. As is common in these cases, a routine clinical chemistry panel revealed no abnormalities. The diagnosis was confirmed based upon markedly elevated resting  $T_4$  levels.



**Fig. 28** Several prominent Heinz bodies (seen as nose-like projections from the red cell surface). Note the lack of polychromasia (Wright's stain x 100).



**Fig. 29** With vital stains, Heinz bodies are much more obvious. In this new methylene blue-stained preparation, they are seen as blue precipitates within the red cell (100x).

## CASE 18

**Signalment:** Ten-year-old female mixed-breed dog

**History:** Polyuria and polydipsia of 3 months' duration with progressive anorexia

HCT	24%	WBC	8,500/ $\mu$ l
Hb	7.8 g/dl	Neutrophils	7,000/ $\mu$ l
RBC	$3.8 \times 10^6$ / $\mu$ l	Lymphocytes	1,000/ $\mu$ l
TP	3.2 g/dl	Monocytes	500/ $\mu$ l
Platelets	Adequate		

**Morphology:** Numerous Burr cells seen

### Description

**Leukogram:** The principal abnormality noted is marginal lymphopenia.

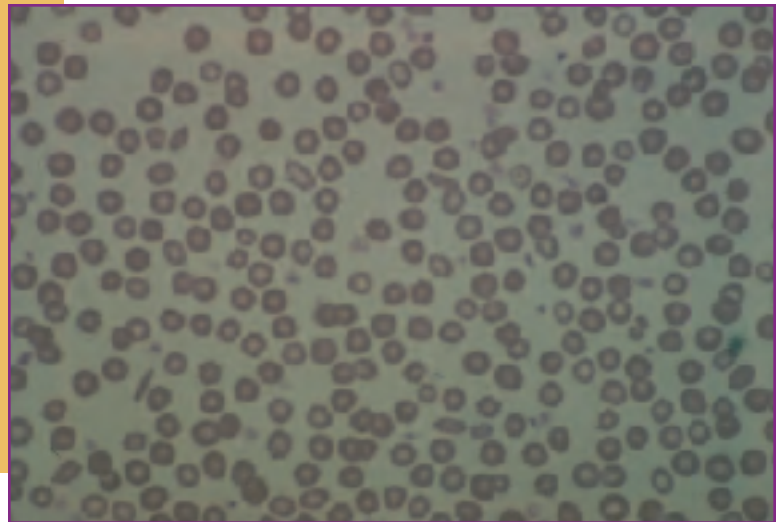
**Erythrogram:** There is a moderate normocytic (MCV = 63 fl), normochromic (MCHC = 32%) anemia with Burr cells. No polychromasia is noted.

**Thrombogram:** Unremarkable.

## Interpretation

1.) Stress leukogram. Marginal lymphopenia strongly suggests high circulating glucocorticoid levels and a stress leukogram.

2.) Non-regenerative anemia with Burr cells. The absence of polychromasia confirms nonregenerative anemia in this patient. Red cell indices within the reference range are expected. Burr cells are elongated (oval) RBCs with ruffled membranes. In humans, spiculated RBCs with Burr cell morphology have often been associated with renal disease. This association is less clear in animals. However, large numbers of spiculated red cells (acanthocytes, Burr cells) in canine blood films have been associated with either liver disease or renal disease. In general, when acanthocytes are predominant, liver disease is more



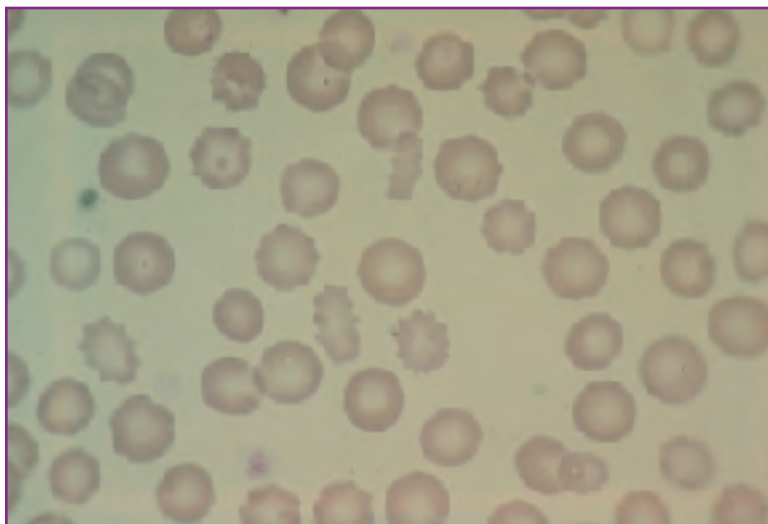
**Fig. 30** Scanning magnification. Poikilocytosis (variable red cell shape) is striking. Numerous elongated red cells (ovalocytes).

---

likely; when Burr cells are prevalent, renal disease should be higher on the differential. Renal disease is also fairly consistently associated with non-regenerative anemia without red cell morphologic changes. Considering the clinical signs, the anemia, and the Burr cells, the possibility of renal disease should be thoroughly investigated in this patient.

## Summary

Clinical chemistry and urinalysis confirmed the diagnosis of renal failure (BUN = 242, creatinine = 4.3, urine specific gravity = 1.009). Renal biopsy established a morphologic diagnosis of end-stage kidney disease (nephrosclerosis). It is of interest that minimal inflammation was seen histologically; this is consistent with the lack of an inflammatory leukogram.



**Fig. 31** High magnification. Elongated red cells with ruffled membranes (Burr cells) have been associated with metabolic disorders, particularly renal disease, in humans and dogs.

## CASE 19

**Signalment:** Five-year-old female  
Coonhound

**History:** Gradually worsening CNS  
signs – dullness, rare  
seizures, occasional circling

HCT	35%	WBC (corrected)	15,500/ $\mu$ l
Hb	11.1 g/dl	Neutrophils	10,000/ $\mu$ l
RBC	$5.2 \times 10^6$ / $\mu$ l	Lymphocytes	3,000/ $\mu$ l
TP	6.5 g/dl	Monocytes	2,500/ $\mu$ l
NRBC	85/100 WBC	Platelet	Adequate

**Morphology:** No polychromasia seen

### Description

**Leukogram:** Total white cell count is within the reference range; however, there is a marked monocytosis.

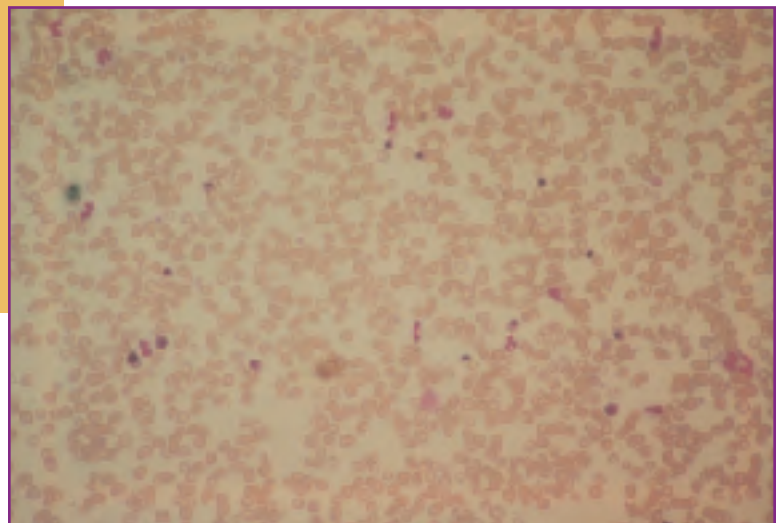
**Erythrogram:** There is a mild anemia with no increase in polychromasia and pronounced inappropriate nucleated red cell response (increased nucleated red cells in the absence of significant polychromasia).

**Thrombogram:** Unremarkable.

## Interpretation

1.) Chronic inflammatory leukogram with tissue necrosis. Monocytosis indicates both inflammation and tissue necrosis. The normal white cell count, absence of a left shift, lack of lymphopenia, and the monocytosis are consistent with chronic inflammation.

2.) Bone marrow stromal damage. An inappropriate nucleated red cell response is usually associated with damage to bone marrow stroma and indiscriminate leakage of immature red cells into circulation. Causes include endotoxemia, high circulating levels of glucocorticoids, fractures, lead poisoning (in dogs), and FeLV disease in cats. Other causes of inappropriately increased numbers of nucleated red cells in circulation include extramedullary hematopoiesis and splenic dysfunction or splenectomy. The degree of inappropriate response is of interpretive significance. Nucleated red cell counts of greater than 10/100 WBC are marked and are most likely the result of lead poisoning in the dog, while in the cat, they most commonly are associated with FeLV-induced marrow disease. In the present case, lead poisoning is the most likely diagnosis. Lead



**Fig. 32** Scanning magnification. Numerous nucleated cells, many of them nucleated red cells, are seen. There also appears to be a left shift.

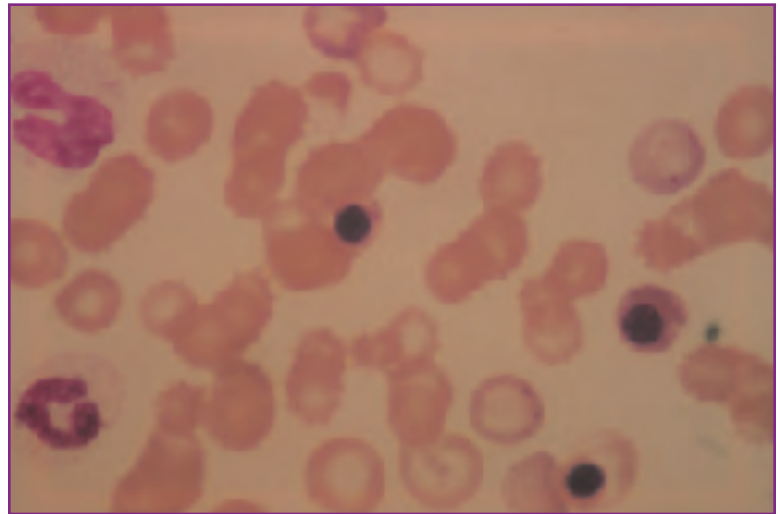
poisoning can also cause tissue necrosis with monocytosis and CNS clinical signs as seen here.

### Summary

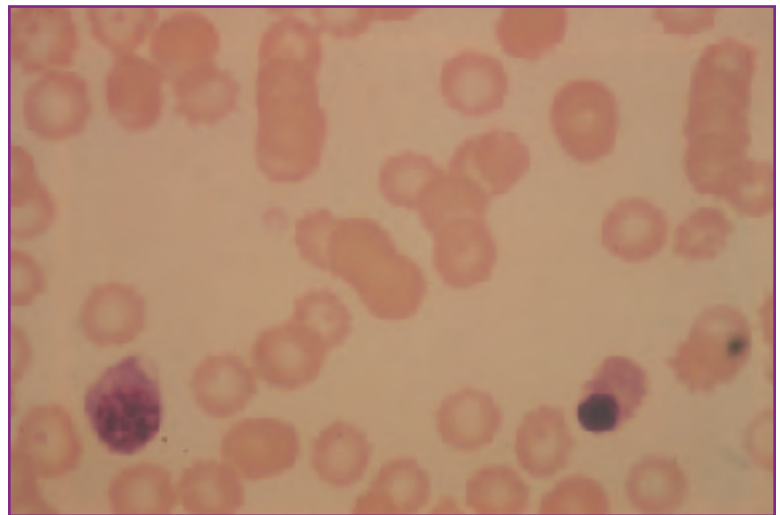
Blood lead levels of 0.7 ppm confirmed the suspected diagnosis of lead poisoning.

### Comment

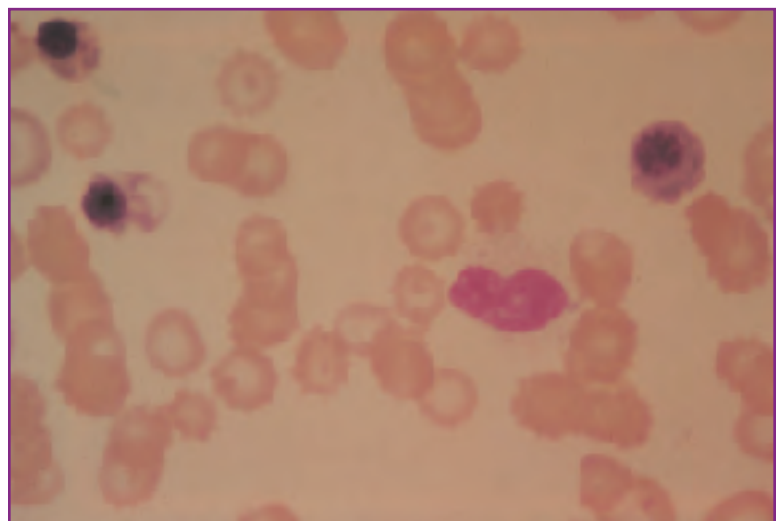
Basophilic stippling of RBCs has long been cited as an important hematologic finding in cases of lead poisoning. However, basophilic stippling is not a constant finding and was not present here. Blood films in this case were made from blood collected with EDTA; basophilic stippling is more easily demonstrated in films made from blood not treated with anticoagulants. When lead poisoning is suspected, it may be useful to prepare several direct blood films for staining and evaluation.



**Fig. 33** High magnification. The number of nucleated red cells is too high for the degree of polychromasia (inappropriate nucleated red cell response). Note that the NRBC (center) is stippled (contains basophilic cytoplasmic precipitates). The two neutrophilic bands (left) have toxic cytoplasm.



**Fig. 34** High magnification. The nucleated red cell (left) is quite immature.



**Fig. 35** High magnification. Three nucleated red cells and a toxic metamyelocyte.

## CASE 20

**Signalment:** Seven-year-old male DSH cat  
**History:** Chronic weight loss and anorexia. At presentation, the cat is cachectic, weak, and depressed, with pale mucous membranes.

HCT	12%	Neutrophils	1,000/ $\mu$ l
Hb	4.0 g/dl	Lymphocytes	500/ $\mu$ l
RBC	$2.6 \times 10^6$ / $\mu$ l	Monocytes	300/ $\mu$ l
TP	6.0 g/dl	Eosinophils	200/ $\mu$ l
NRBC	400/100 WBC	Nucleated cells	30,000/ $\mu$ l
Platelets	Reduced		(6,000/ $\mu$ l corrected)
Blasts & unclassified			4,000/ $\mu$ l

**Morphology:** Very high nucleated red cell count with recognizable red cell precursors in all stages of differentiation. Remaining nucleated cells are largely blasts and unclassified cells. Blasts appear to be of both red cell and granulocytic lines.

### Description

**Leukogram:** Leukopenia with marked neutropenia, lymphopenia, and increased numbers of blasts and unclassified cells.

**Erythrogram:** Severe normocytic, normochromic anemia with profound metarubricytosis.

**Thrombogram:** Thrombocytopenia.

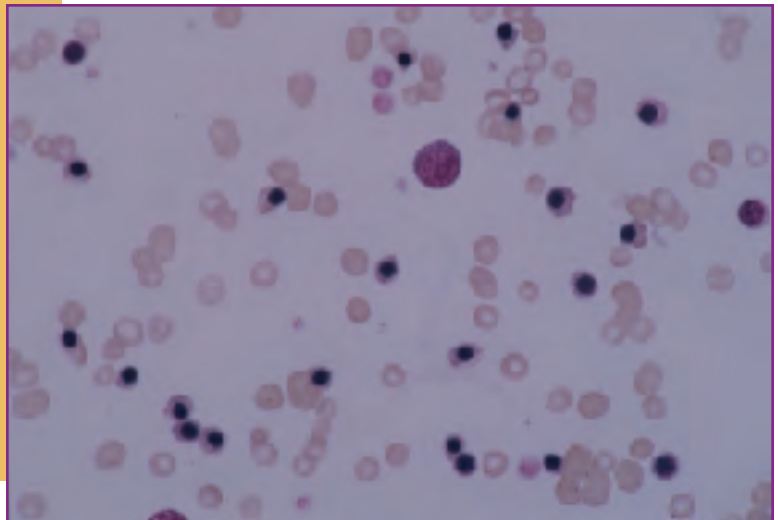
## Interpretation

1.) Pancytopenia. Mature forms of all cell lines (white cell, red cell, and platelet) are present in markedly reduced numbers. This finding alone suggests marrow disease and would warrant marrow evaluation. In the cat, the primary concerns with a history of chronic disease are FeLV or FIP infection.

2.) Inappropriate nucleated red cell response. Metarubricytosis in the absence of polychromasia is an inappropriate nucleated red cell response and suggests marrow stromal disease. In this patient, where numerous stages of RBC precursors are seen in the blood, it is highly suggestive of FeLV related marrow disease. Because of the marked metarubricytosis, total nucleated cell count must be corrected. This is done according to the following formula:

$$\text{Total nucleated cell count} \times \frac{100}{100 + \text{NRBC}/100 \text{ WBC}} = \text{Corrected WBC count}$$

$$\text{In this case, } 30,000 \times \frac{100}{100 + 400} = 6,000$$



**Fig. 36** Low magnification shows large numbers of nucleated red cells. Note that the film is very thin, suggesting severe anemia (Wright's stain x 50).

3.) Probable FeLV related erythroleukemia. The presence of numerous blasts and abnormal unclassified cells further supports the suggestion of FeLV related disease with a leukemic phase. Because blasts and poorly differentiated precursors of both red cell and granulocyte lineage are seen, erythroleukemia (combined red and white cell leukemia) is the best specific diagnosis.

### Comment

The cat tested positive for FeLV and negative for FIP.

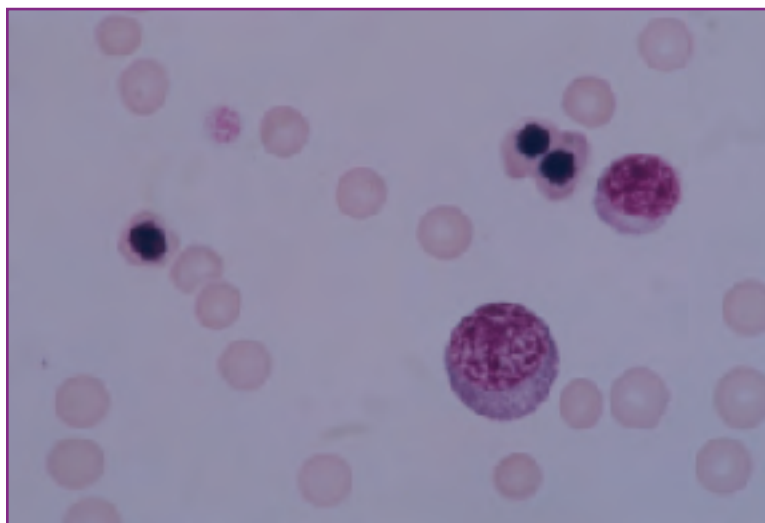


Fig. 37 Three metarubricytes, a lymphocyte, and a nucleated cell that is difficult to classify (Wright's stain x 100).

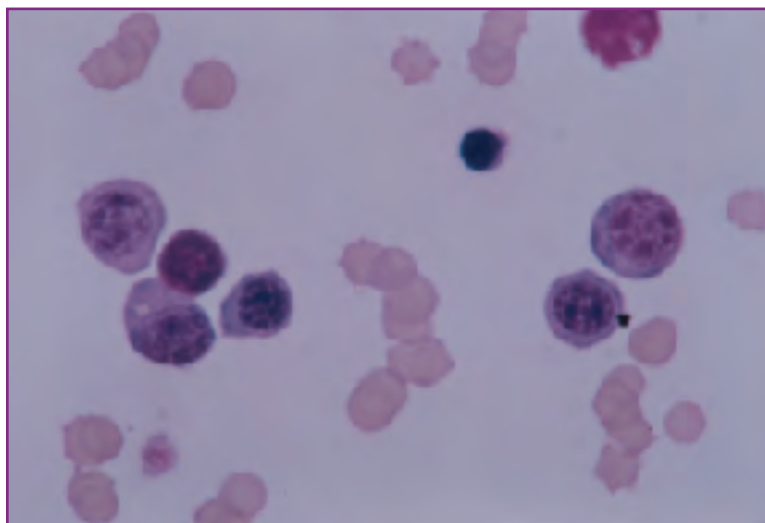


Fig. 38 Various stages of nucleated red cell differentiation (Wright's stain x 100).

## CASE 21

**Signalment:** Four-year-old female Persian cat  
**History:** Sudden onset epistaxis with numerous petechiae seen on physical examination

HCT	30%	WBC	11,950/ $\mu$ l
Hb	10.0 g/dl	Neutrophils	10,000/ $\mu$ l
RBC	$6.2 \times 10^6$ / $\mu$ l	Lymphocytes	1,100/ $\mu$ l
TP	6.7 g/dl	Monocytes	850/ $\mu$ l
Platelets	Rare		

**Bone marrow examination:** Very cellular. Erythroid hyperplasia with left shift and marked megakaryocytic hyperplasia evident.

### Description

**Leukogram:** All leukocyte values are within the reference range but lymphocyte numbers are marginally low (marginal lymphopenia).

**Erythrogram:** There is a mild anemia with no reported polychromasia. Computed red cell indices are within the reference range (MCV = 47 fl, MCHC = 33%).

**Thrombogram:** Thrombocytopenia.

## Interpretation

1.) Stress leukogram. Marginal lymphopenia is suggestive of stress.

2.) Consumptive/destructive thrombocytopenia. Thrombocytopenias can result from a lack of production of platelets by the marrow, sequestration of platelets in peripheral tissues (hypersplenism), consumption of platelets in hypercoagulation syndromes (DIC), or destruction of platelets by anti-platelet antibodies (immune-mediated thrombocytopenia). Hypersplenism is rare in animals and is associated with an enlarged spleen, which was not present in this case. Production thrombocytopenias are differentiated from consumption/destruction thrombocytopenias with bone marrow evaluation. Production thrombocytopenias are characterized by reduced numbers of marrow megakaryocytes, while consumption/destruction thrombocytopenias have normal to increased numbers of megakaryocytes. Marrow morphology in this cat strongly suggests a consumption/destruction problem. Given the absence of an inflammatory leukogram, DIC and consumption thrombocytopenia are highly unlikely. This is, therefore, most likely a case of immune-mediated thrombocytopenia.

3.) Anemia of uncertain origin. The anemia is mild, and, based on peripheral blood findings, non-regenerative. However, bone marrow morphology indicates red cell regeneration. Either this is a regenerative anemia (blood loss or hemolytic) in its earliest stages (before peripheral reticulocytosis has had time to occur – 72 to 96 hours.), or an immune-mediated marrow disease directed against late stage red cell precursors. Repeated CBCs should help clarify the situation; if truly regenerative, polychromasia will be present on blood films within the next few days.

## Summary

Blood films taken within 24 hours of presentation contained significant numbers of reticulocytes, thus confirming the regenerative nature of the anemia. No spherocytes were observed. A presumptive diagnosis of blood loss anemia secondary to thrombocytopenia was made. Steroid therapy was initiated to treat the presumed immune-mediated thrombocytopenia. A rising platelet count was seen within 24 hours of therapy induction. Platelet counts had returned to normal by 10 days, confirming the diagnosis of immune-mediated thrombocytopenia.



## CASE 22

**Signalment:** One-year-old male Cocker Spaniel

**History:** Severe depression and severe, acute diarrhea with dark tarry stools

HCT	33%	WBC	6,000/ $\mu$ l
Hb	11.0 g/dl	Bands	1,000/ $\mu$ l
RBC	$5.0 \times 10^6$ / $\mu$ l	Neutrophils	1,500/ $\mu$ l
TP	8.0 g/dl	Lymphocytes	500/ $\mu$ l
Platelets	Rare	Monocytes	3,000/ $\mu$ l

**Morphology:** Neutrophils and bands are foamy and basophilic. Moderate poikilocytosis characterized primarily by schizocytes.

### Description

**Leukogram:** There is a leukopenia characterized by a marked neutropenia with a left shift (degenerative left shift), a profound lymphopenia, and a marked monocytosis.

**Erythrogram:** There is a mild anemia with poikilocytosis characterized primarily as schizocytosis. There is hyperproteinemia. There is no polychromasia.

**Thrombogram:** Marked thrombocytopenia.

## Interpretation

1.) Overwhelming inflammation with tissue necrosis. The left shift and monocytosis indicate inflammation. Monocytosis also indicates tissue necrosis with demand for phagocytosis. The low total white cell count and neutropenia suggest an inability of marrow production to keep pace with tissue demand; hence, the inflammatory process is severe and overwhelming with a guarded prognosis.

2.) Stress leukogram. Marked lymphopenia indicates stress. The degree of lymphopenia is so great that other possible causes of lymphopenia should also be considered.

3.) Non-regenerative anemia. Anemia without polychromasia is non-regenerative. The degree of anemia may be more severe than is indicated by the red cell data because the animal appears to be dehydrated (elevated plasma protein in the face of severe diarrhea suggests hemoconcentration from dehydration, other indicators of hemoconcentration could be found in urinalysis data and chemistry panels, eg, concentrated urine specific gravity, elevated BUN, creatinine, serum albumin, and electrolytes). Considering that thrombocytopenia is also present and that stools are tarry, the possibility of an early blood loss anemia (before polychromasia becomes evident) should be considered.

4.) Possible DIC. The combination of thrombocytopenia and schizocytosis on the peripheral blood film suggest the possibility of disseminated intravascular coagulopathy. A full DIC panel (prothrombin time, activated partial thromboplastin time, fibrin split products, fibrinogen, and platelet count) should be run. If three of the five tests are abnormal, DIC is confirmed. Overwhelming inflammatory disease is frequently associated with secondary DIC.

## Summary

The final diagnosis in this patient is parvoviral enteritis with secondary bacterial enteritis, endotoxemia and DIC. Fibrin split products were elevated, PT and PTT were prolonged, and platelet count was reduced. Blood loss through the intestinal tract was the cause of the anemia. Within 24 hours of presentation, polychromasia became apparent on peripheral films.

## CASE 23

**Signalment:** Two-year-old male DSH cat  
**History:** Weight loss, anorexia, and recent diarrhea

HCT	35%	WBC	2,200/ $\mu$ l
Hb	11.7 g/dl	Neutrophils	500/ $\mu$ l
RBC	$6.2 \times 10^6$ / $\mu$ l	Lymphocytes	700/ $\mu$ l
TP	7.0 g/dl	Monocytes	1,000/ $\mu$ l
Platelets	Reduced		

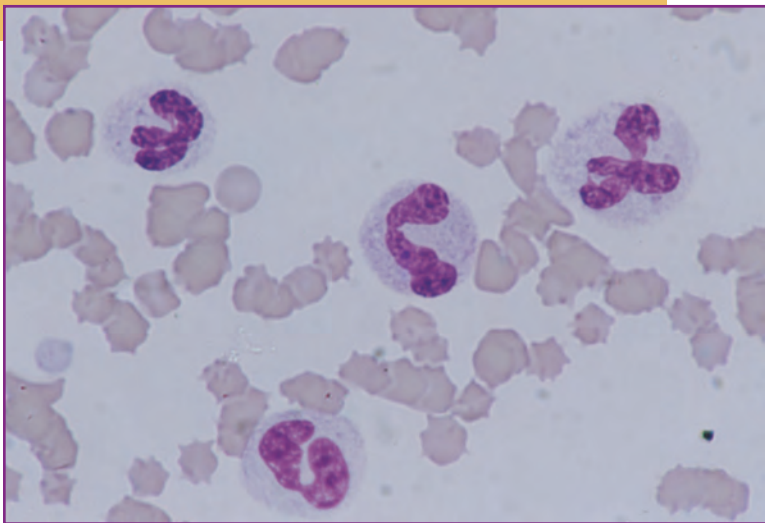
**Morphology:** Neutrophils seen are extremely toxic.

### Description

**Leukogram:** There is a marked leukopenia characterized by a marked neutropenia and lymphopenia and systemic toxemia.

**Erythrogram:** There is a minimal to mild anemia in the absence of polychromasia.

**Thrombogram:** Thrombocytopenia.



**Fig. 39** High magnification. Four toxic neutrophils with foamy basophilic cytoplasm and scattered Döhle bodies. The neutrophil at upper right is a giant form and has unusual nuclear shape.

## Interpretation

1.) Possible marrow disease with systemic toxemia. There are no absolute indicators of inflammation in the leukogram and concomitant thrombocytopenia suggests a possible marrow production problem. The marked neutrophil toxicity coupled with leukopenia and neutropenia suggests a possible secondary overwhelming bacterial infection.

2.) Superimposed stress. The marked lymphopenia is indicative of high circulating levels of glucocorticoids.

3.) Minimal to mild non-regenerative anemia. Reduction in red cell mass is so mild that it is probably not clinically significant at this time. However, red cell data should be closely monitored to see if anemia develops further. At this point, it is normocytic, normochromic and non-regenerative.

4.) Thrombocytopenia. Thrombocytopenia may be the result of a marrow production problem or may reflect possible DIC associated with overwhelming bacterial infection. Both a bone marrow evaluation and a full DIC panel are warranted.

## Summary

Hematologic data from this cat are similar to that from the dog in Case 22, but clear indicators of inflammation are lacking. This is a case of feline panleukopenia with secondary bacterial enteritis and endotoxemia. DIC was confirmed by elevated fibrin split products, prolonged prothrombin time, and prolonged activated partial thromboplastin time. Marrow evaluation revealed a production problem characterized by hypoplasia and necrosis probably caused by feline panleukopenia virus infection. Peripheral red cell data do not yet reflect the production problem because red cell lifespan is longer than that of leukocytes and platelets.

## CASE 24

**Signalment:** Four-year-old female  
Collie-Labrador mix

**History:** Acute onset lethargy with  
pale mucous membranes

HCT	21%	WBC	18,000/ $\mu$ l
Hb	7.0 g/dl	Bands	1,000/ $\mu$ l
RBC	$3.1 \times 10^6/\mu$ l	Neutrophils	14,000/ $\mu$ l
TP	6.8 g/dl	Lymphocytes	1,500/ $\mu$ l
Platelets	Reduced	Monocytes	1,500/ $\mu$ l

Reticulocyte count = 4%

### Description

**Leukogram:** There is mild leukocytosis with neutrophilia, left shift, marginal lymphopenia, and mild monocytosis.

**Erythrogram:** There is a moderately severe anemia with reticulocytosis. The absolute reticulocyte count is 124,000/ $\mu$ l. MCV and MCHC (computed) are within the reference ranges.

**Thrombogram:** Thrombocytopenia.

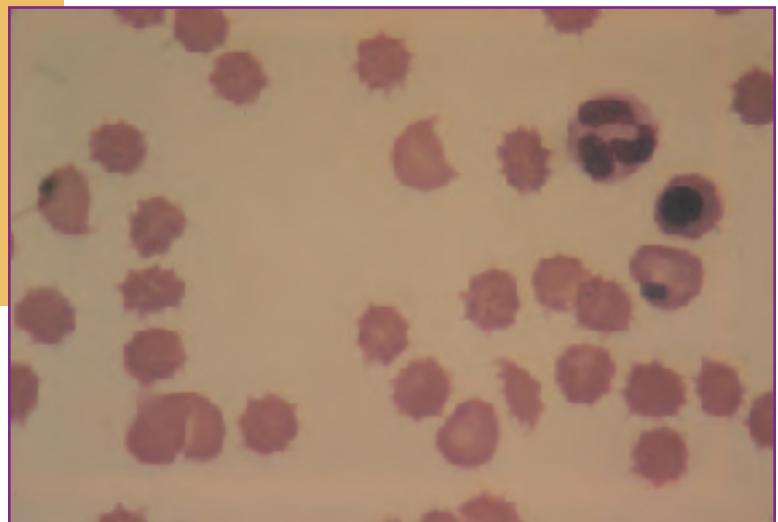
### Interpretation

- 1.) Inflammatory leukogram with tissue necrosis. Neutrophilia with a left shift indicates inflammation. Mild monocytosis indicates tissue necrosis.
- 2.) Superimposed stress. Marginal lymphopenia suggests high circulating glucocorticoids (stress).
- 3.) Regenerative anemia. Anemia with an absolute reticulocyte count of 124,000/ $\mu$ l is regenerative. Differentiation between blood loss and hemolysis is not possible at this time. The presence of noticeable schizocytes (see *Figs. 28, 29*) suggests that microangiopathic hemolysis is at least partly responsible.
- 4.) Possible DIC. The combination of inflammatory leukogram, thrombocytopenia, and schizocytes on the blood film suggest possible DIC. As in Cases 17 and 18, a full DIC panel is warranted.

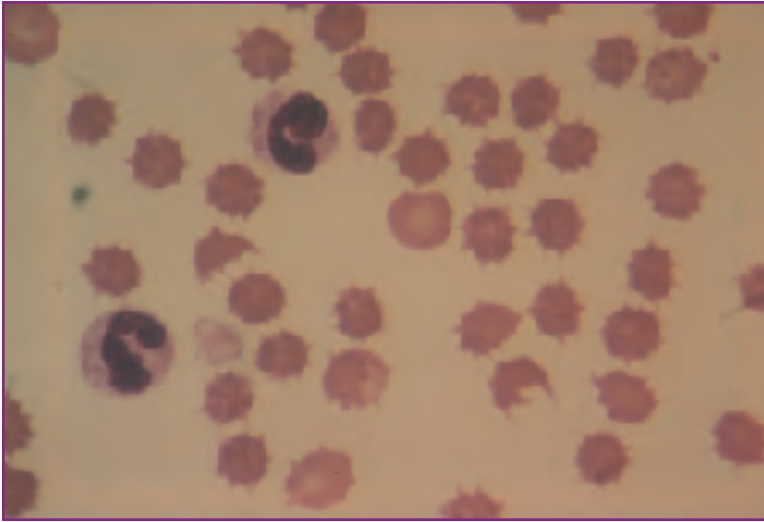
### Summary

Considered collectively, hematologic data suggests an

*Continued*



**Fig. 40** High magnification. Note the absence of platelets. Three red cell fragments (schizocytes).



**Fig. 41** High magnification. Two schizocytes.

inflammatory process complicated by DIC with associated regenerative anemia. The anemia may be complex, possibly resulting from a combination of blood loss and microangiopathic hemolysis. The actual diagnosis in this patient was malignant mammary carcinoma with widespread metastasis. At the time of presentation, there was hemothorax secondary to bleeding tumor nodules on the surface of the lung. DIC was also confirmed with additional laboratory tests.

## CASE 25

**Signalment:** Three-year-old female Persian cat

**History:** Chronic, intermittent cough and occasional wheezing

HCT	40%	WBC	17,000/ $\mu$ l
Hb	13.1 g/dl	Neutrophils	10,000/ $\mu$ l
RBC	$8.0 \times 10^6$ / $\mu$ l	Lymphocytes	2,000/ $\mu$ l
		Eosinophils	4,500/ $\mu$ l
Platelets	Adequate	Monocytes	500/ $\mu$ l

### Description

**Leukogram:** There is a high normal leukocyte count with a marked eosinophilia.

**Erythrogram:** Unremarkable.

**Thrombogram:** Unremarkable.

### Interpretation

Inflammatory leukogram with systemic hypersensitivity. Eosinophilia, if persistent, is a clear indicator of both inflammation and systemic hypersensitivity. In cats, potential causes include eosinophilic granuloma complex (the systemic linear plaque form), feline asthma, systemic mast cell tumor, flea-bite dermatitis, allergic gastroenteritis, and parasitic infections with a systemic phase. In this case, considering the clinical presentation, feline asthma is at the top of the differential



# Hematology Reference Ranges

	<b>Units</b>	<b>Dog</b>	<b>Cat</b>
<b>Total Protein (TP)</b>	g/dl	6.0 - 8.0	6.0 - 8.0
<b>HCT</b>	%	37 - 55	30 - 45
<b>Hb</b>	g/dl	12 - 18	8 - 15
<b>RBC</b>	$\times 10^6/\mu\text{l}$	5.5 - 8.5	5.0 - 10.0
<b>WBC</b>	$\times 10^3/\mu\text{l}$	6 - 17	6 - 18
<b>Bands</b>	$/\mu\text{l}$	0 - 300	0 - 300
<b>Neutrophils</b>	$/\mu\text{l}$	3,000 - 12,000	3,000 - 12,000
<b>Lymphocytes</b>	$/\mu\text{l}$	1,000 - 5,000	1,500 - 7,000
<b>Monocytes</b>	$/\mu\text{l}$	150 - 1,350	50 - 850
<b>Eosinophils</b>	$/\mu\text{l}$	100 - 1,250	100 - 1,500
<b>MCV</b>	fl	60 - 75	40 - 55
<b>MCHC</b>	g/dl	32 - 36	30 - 36
<b>Fibrinogen</b>	mg/dl	200 - 400	150 - 300
<b>Platelets</b>	$\times 10^5/\mu\text{l}$	2 - 9	3 - 7
<b>Prothrombin Time</b>	Seconds	5.5 - 7.9	6.4 - 9.6
<b>Partial Thromboplastin Time (APTT or PTT)</b>	Seconds	11.4 - 16.4	9.3 - 18.7
<b>FSPs (Fibrin/Fibrinogen Split Products)</b>	g/ml	<10	<10

# Index of Figures

*All slides courtesy of Alan H. Rebar, DVM, PhD.*

## Chapter 1: Leukocytes in Health & Disease

- Fig. 1 .....Normal circulating neutrophils.
- Fig. 2 .....Normal canine eosinophil (left), reactive lymphocyte (right).
- Fig. 3 .....Normal feline eosinophil.
- Fig. 4 .....Normal canine basophil.
- Fig. 5 .....Normal canine basophil.
- Fig. 6 .....Normal feline basophil (left), normal neutrophil (right).
- Fig. 7 .....Normal canine monocytes.
- Fig. 8 .....Normal small lymphocyte (round nucleus), three neutrophils, and normal band cell (right).
- Fig. 9 .....Blast-transformed (reactive, activated) lymphocyte.
- Fig. 10 .....Reactive lymphocyte (lower center), three neutrophils, and a monocyte (top center).
- Fig. 11 .....Reactive lymphocyte (center) and four neutrophils.
- Fig. 12 .....Reactive lymphocyte.
- Fig. 13 .....Reactive lymphocyte.
- Fig. 14 .....Fully differentiated plasma cell.
- Fig. 15 .....Toxic band cell with foamy, basophilic cytoplasm.
- Fig. 16 .....Giant toxic band with foamy, basophilic cytoplasm and giant, irregular nucleus.
- Fig. 17 .....Two toxic neutrophils and a toxic band. Note the unusual nuclear shape.
- Fig. 18 .....Two toxic neutrophils with Döhle bodies.
- Fig. 19 .....Atypical lymphocyte.

## Chapter 2: Erythrocytes in Health & Disease

- Fig. 1 .....Normal canine blood film. Scanning magnification. RBCs are uniform in size, shape, and color, and feature prominent central pallor.
- Fig. 2 .....Canine blood film with increased polychromasia. Scanning magnification. Polychromatophils are bluish and generally larger than mature cells.
- Fig. 3 .....High magnification of Fig. 2. This represents a regenerative anemia with marked polychromasia. Note the marked separation of RBCs.
- Fig. 4 .....Low magnification of a new methylene blue-stained blood film. Reticulocytes stand out due to blue stained reticulum visible at this magnification. This represents a highly regenerative anemia.
- Fig. 5 .....High magnification of Fig. 4. Reticulocytes with precipitated blue reticulum are obvious. In dogs, all would be counted; in cats, only those with abundant precipitate (aggregate reticulocytes) would be counted. Several leukocytes are also present.
- Fig. 6 .....Canine immune-mediated hemolytic anemia. The anemia is highly regenerative with marked polychromasia. A spherocyte (arrow).
- Fig. 7 .....A second case of canine immune-mediated hemolytic anemia with numerous spherocytes.
- Fig. 8 .....Feline immune-mediated hemolytic anemia. Spherocytes are numerous but less obvious due to the lack of central pallor in the normal RBCs.
- Fig. 9 .....Saline-diluted wet preparation demonstrating autoagglutination.
- Fig. 10 .....Heinz body hemolytic anemia in the dog. Several cells with nose-like projections (Heinz bodies) and several polychromatophils.



- Fig. 11 .....Canine Heinz body hemolytic anemia, new methylene blue stain. Several cells with Heinz bodies (upper left). Two reticulocytes with aggregated reticulum (right center).
- Fig. 12 .....Feline hyperthyroidism. Numerous cells have obvious Heinz bodies projecting from their surfaces, but anemia is not present.
- Fig. 13 .....Canine hemobartonellosis. Several cells have chains of beaded basophilic organisms on their surfaces. Several polychromatophils and a schizocyte.
- Fig. 14 .....Feline hemobartonellosis. Several polychromatophils are present. The red cell (center) has several prominent *Hemobartonella* bodies.
- Fig. 15 .....Canine babesiosis. The cell (center) has two teardrop-shaped organisms. A red cell (upper right) with a single organism.
- Fig. 16 .....Microangiopathic hemolysis in disseminated intravascular coagulopathy (DIC). Numerous schizocytes.
- Fig. 17 .....Hepatic hemangiosarcoma in a dog. Two acanthocytes (center). A schizocyte (left). Numerous target cells, which can be precursors to acanthocytes. Polychromasia indicates a mildly regenerative anemia.
- Fig. 18 .....Canine glomerulonephritis. Numerous Burr cells.
- Fig. 19 .....FeLV(peripheral blood film). Two megaloblasts.
- Fig. 20 .....Bone marrow smear from the same case as Fig. 19. A large megaloblast (right).
- Fig. 21 .....Iron deficiency anemia. Numerous red cells have exaggerated areas of central pallor; some are smaller than normal. A red cell fragment (schizocyte-center).
- Fig. 22 .....Myelofibrosis in the dog. A dacryocyte (center and top center). Numerous ovalocytes.

## Chapter 5: Case Studies

- Fig. 1 .....Case #4. A band cell with slight toxicity (left). Note the foamy, granular, slightly basophilic cytoplasm. A normal monocyte (right).
- Fig. 2 .....Case #4. Two band cells and a mature neutrophil.
- Fig. 3 .....Case #4. A toxic band cell (left), and a toxic metamyelocyte (right). The cytoplasm of both cells is too blue.
- Fig. 4 .....Case #4. A toxic neutrophil with foamy, basophilic cytoplasm and Döhle bodies.
- Fig. 5 .....Case #5. On scanning magnification, a monocytosis is obvious. Four monocytes and seven neutrophils.
- Fig. 6 .....Case #6. A reactive lymphocyte with large nucleus, lacy chromatin pattern, and basophilic cytoplasm.
- Fig. 7 .....Case #6. Two reactive lymphocytes.
- Fig. 8 .....Case #8. Low magnification reveals a leukocytosis with neutrophilia and left shift.
- Fig. 9 .....Case #8. High magnification. A giant toxic band cell (center). Note the blue cytoplasm (Wright's stain x 100).
- Fig. 10 .....Case #8. Two toxic neutrophils with foamy, basophilic cytoplasm (Wright's stain x 100).
- Fig. 11 .....Case #8. A toxic band cell (left), and a toxic neutrophil (right). Again, note the foamy, basophilic cytoplasm (Wright's stain x 100).
- Fig. 12 .....Case #9. Aspirate of a normal lymph node. Normal small lymphocytes predominate with several larger prolymphocytes.
- Fig. 13 .....Case #9. Aspirate of a lymph node with lymphoma. The majority of the cells are large blasts with very large nuclei and prominent nucleoli.
- Fig. 14 .....Case #10. Low magnification of pleural fluid. Normal small lymphocytes predominate. Red cells are seen in the background. This is typical of a chylous effusion.

---

*All slides courtesy of Alan H. Rebar, DVM, PhD.*

- Fig. 15 .....Case #10. High magnification of Fig. 14. Normal small lymphocytes.
- Fig. 16 .....Case #11. Two normal eosinophils.
- Fig. 17 .....Case #13. Scanning magnification. Note the extremely pale staining of the RBCs.
- Fig. 18 .....Case #13. High magnification. Note the marked central pallor of the RBCs. This is typical of iron deficiency.
- Fig. 19 .....Case #13. High magnification. A schizocyte (left center).
- Fig. 20-22..Case #14. Numerous RBCs parasitized by *Hemobartonella felis* are seen in all three figures. Both ring forms as well as chains of coccal forms are present (Wright's stain x 100).
- Fig. 23 .....Case #15. Scanning magnification. Note the marked variability in red cell size (anisocytosis).
- Fig. 24 .....Case #15. Scanning magnification. A left shift and two nucleated red cells.
- Fig. 25 .....Case #15. High magnification. Note the presence of spherocytes. Several polychromatophils (center). Changes are consistent with immune-mediated hemolytic anemia.
- Fig. 26 .....Case #16. Scanning magnification. Monocytosis is apparent. Red cells exhibit anisocytosis and polychromasia.
- Fig. 27 .....Case #16. High magnification. Two polychromatophils and nucleated red cells (left). Numerous red cells have multiple finger-like projections (acanthocytes). Platelets are obvious.
- Fig. 28 .....Case #17. Several prominent Heinz bodies (seen as nose-like projections from the red cell surface). Note the lack of polychromasia (Wright's stain x 100).
- Fig. 29 .....Case #17. With vital stains, Heinz bodies are much more obvious. In this new methylene blue-stained preparation, they are seen as blue precipitates within the red cell (100x).
- Fig. 30 .....Case #18. Scanning magnification. Poikilocytosis (variable red cell shape) is striking. Numerous elongated red cells (ovalocytes).
- Fig. 31 .....Case #18. High magnification. Elongated red cells with ruffled membranes (Burr cells) have been associated with metabolic disorders, particularly renal disease, in humans and dogs.
- Fig. 32 .....Case #19. Scanning magnification. Numerous nucleated cells, many of them nucleated red cells. There also appears to be a left shift.
- Fig. 33 .....Case #19. High magnification. The number of nucleated red cells is too high for the degree of polychromasia (inappropriate nucleated red cell response). Note that the nucleated red cell (center) is stippled (contains basophilic cytoplasmic precipitates). The two neutrophilic bands (left) have toxic cytoplasm.
- Fig. 34 .....Case #19. High magnification. The nucleated red cell (left) is quite immature.
- Fig. 35 .....Case #19. High magnification. Three nucleated red cells and a toxic metamyelocyte.
- Fig. 36 .....Case #20. Low magnification shows large numbers of nucleated red cells. Note that the film is very thin, suggesting severe anemia (Wright's stain x 50).
- Fig. 37 .....Case #20. Three metarubricytes, a lymphocyte, and a nucleated cell that is difficult to classify (Wright's stain x 100).
- Fig. 38 .....Case #20. Various stages of nucleated red cell differentiation (Wright's stain x 100).
- Fig. 39 .....Case #23. High magnification. Three extremely toxic neutrophil-series cells.
- Fig. 40 .....Case #24. High magnification. Note the absence of platelets. Three red cell fragments (schizocytes).
- Fig. 41 .....Case #24. High magnification. Two schizocytes.

# Glossary of Terms

## -A-

**activated lymphocytes:** Antigen-stimulated (blast-transformed, reactive) lymphocytes. These lymphocytes are actively gearing up to produce antibodies or lymphokines. They have morphologic features of active protein producing cells: lacy chromatin (primarily euchromatin) and abundant blue cytoplasm rich in RNA.

**adherence:** Stage II of phagocytosis. The binding of phagocyte surface receptors to microorganisms and other foreign matter.

**autoagglutination:** Three-dimensional clumping of erythrocytes as a result of cross-linking of erythrocytes by antibodies; this feature confirms diagnosis of immune-mediated disease.

## -C-

**cell-mediated immunity:** Refers to the production of lymphokines of effector T lymphocytes in response to antigenic stimulation.

**chemotaxis:** Stage I of phagocytosis. The directed movement of phagocytes along an increasing gradient of chemoattractant molecules.

## -E-

**endomitosis:** Nuclear division without cytoplasmic division. Megakaryoblasts mature to megakaryocytes via endomitosis.

**euchromatin:** Chromatin comprised mostly of active genes (DNA) that control cell function by serving as templates for messenger RNA (mRNA) formation, which in turn regulates cellular protein synthesis. Euchromatin has a granular, lacy pattern in Romanowsky-stained preparations. Monocyte nuclei contain mostly euchromatin. (In contrast, heterochromatin contains mostly inactive DNA whose active sites are bound to histone (protein)

suppressors, which inhibit gene activity.

Heterochromatin stains deep purple in Romanowsky-stained preparations. Neutrophil nuclei contain primarily heterochromatin.)

**erythropoietin:** The primary growth factor regulating committed red cell production and differentiation in the bone marrow. This hormone is produced primarily in the juxtaglomerular apparatus of the kidney, in response to microenvironmental variations in oxygen tension.

## -G-

**golgi zones:** Membranous perinuclear organelle which is the primary intracellular site where protein is packaged for secretion.

## -H-

**Heinz bodies:** Precipitates of hemoglobin that occur as a result of oxidation of hemoglobin. Heinz bodies often are attached to the inner red cell membrane. Because they are rigid, fixed precipitates, they cause intravascular lysis as red cells traverse tortuous vascular capillary spaces.

**humoral immunity:** Refers to the production of antibodies directed against specific antigens by effector B lymphocytes (plasma cells).

## -I-

**immunocytic system:** The "specific immune system" comprised of the circulating lymphocytes (B lymphocytes and T lymphocytes). B lymphocytes produce antibodies while T lymphocytes are responsible for lymphokine production. Lymphocyte products are released in response to specific antigens.

**internalization:** Stage III of phagocytosis. The process by which adhered particles (microorganisms) are

---

taken into a phagocyte for killing and digestion. The process involves invagination of the cell membrane and the formation of a phagocytic vacuole.

### **-L-**

**lymphokines:** Small, biologically active molecules released by antigen-stimulated (blast-transformed, activated, reactive) lymphocytes. These molecules moderate the immune response and may be capable of destroying other cells and microorganisms. Lymphokines are the "molecular hormones" of the immunocytic system.

### **-N-**

**non-specific immune system:** Another name for the phagocytic system. Phagocytes adhere to and ingest a variety of foreign material on contact.

### **-O-**

**opsonization:** The process by which microorganisms and foreign proteins become coated by molecules for which phagocytes have specific surface receptors. The coating molecules—antibodies and complement fragments—are called *opsonins*. Once coated by opsonins, a microorganism or foreign protein is *opsonized*. Opsonization facilitates adherence (stage II of phagocytosis).

### **-P-**

**phagocytic system:** The "non-specific immune system" comprised of circulating phagocytes: neutrophils and cells of the monocyte/ macrophage continuum. These cells establish the first line of defense against invading microorganisms.

**phagocytosis:** The process of ingestion, killing, and digestion of etiologic agents by cells of the phagocytic system. Non-living foreign material may also be ingested and digested by phagocytes.

**polychromatophils:** Large, bluish-red cells seen in low numbers in normal canine and feline blood films. These immature red cells stain bluish because of a lower than normal hemoglobin concentration and a slightly higher than normal amount of cytoplasmic RNA.

**polycythemia:** Increased circulating red cell mass indicated by elevations in hematocrit, hemoglobin, and total red cell count.

**polycythemia vera:** A myeloproliferative disease characterized by overproduction of all marrow cellular elements. Clinical findings are generally referable to increased circulating red cell mass.

### **-S-**

**specific immune system:** Another name for the immunocytic system. Immunocyte response is specific in that antibodies and lymphokines are released in response to specific antigens.

# Suggested Reading

1. Boon, G.D.; Rebar, A.H.: The Clinical Approach to Disorders of Hemostasis. *Textbook of Veterinary Internal Medicine; Diseases of the Dog and Cat*, 3rd Ed. (S.J. Ettinger, ed.). W.B. Saunders, Philadelphia, Pa., 1989; pp 105-108.
2. Breitschwerdt, E.B.: Infectious Thrombocytopenia in Dogs. *Comp Cont Ed* 10:1177, 1988.
3. Butcher, E.C.: Cellular and Molecular Mechanisms that Direct Leukocyte Traffic. *Am J Pathol* 136:3, 1990.
4. Cain, G.R.; Suzuki, Y.: Presumptive Neonatal Isoerythrolysis in Cats. *JAVMA* 187:46, 1985.
5. Calvert, C.A.; Greene, C.E.: Bacteremia in Dogs: Diagnosis, Treatment, and Prognosis. *Comp Cont Ed* 8:179, 1986.
6. Center, S.A. et al: Eosinophilia in the Cat: A Retrospective Study of 312 Cases (1975 to 1986). *J Am Anim Hosp Assoc* 26:349, 1990.
7. Christopher, M.M.: Relationship of Endogenous Heinz Bodies to Disease and Anemia in Cats: 120 Cases. *JAVMA* 194:1089, 1989.
8. Corcoran, B.M. et al: Pulmonary Infiltration with Eosinophils in 14 Dogs. *J Small Anim Pract* 32:494, 1991.
9. Cotter, S.M.: Autoimmune Hemolytic Anemia in Dogs. *Comp Cont Ed* 14:53-56; 1992.
10. Cotter, S.M.; Holzworth, J.: Disorders of the Hematopoietic System. *Diseases of the Cat: Medicine and Surgery*, (J. Holzworth, ed). W.B. Saunders, Philadelphia, Pa., 1987, pp 755-807.
11. DiBartola, S.P. et al: Clinicopathologic Findings Associated with Chronic Renal Disease in Cats: 74 Cases (1973-1984). *JAVMA* 190:1196, 1987.
12. Duncan, J. et al: Erythrocytes, Leukocytes, Hemostasis. *Veterinary Laboratory Medicine*, 3rd Ed. Iowa State University Press, Ames, 1994; pp 3-61, 75-93.
13. Feldman, B.F.: Platelet Dysfunction. *Textbook of Veterinary Internal Medicine; Diseases of Dog and Cat*, 3rd Ed. (S.J. Ettinger, ed.), W.B. Saunders, Philadelphia, Pa., 1989, pp 2265-2279.
14. Giger, U. et al: Inherited Phosphofructokinase Deficiency in Dogs with Hyperventilation-Induced Hemolysis: Increased *in vitro* and *in vivo* Alkaline Fragility of Erythrocytes. *Blood* 65:345, 1985.
15. Gorman, N.T.; Werner, L.L.: Immune-mediated Diseases of the Dog and Cat. I, II, III, IV. *Br Vet J* 142:395, 403, 491, 498, 1986.
16. Greene, C.E.; Harvey, J.W.: Canine Ehrlichiosis. *Infectious Diseases of Dogs and Cats*, (C.E. Greene, ed.), W.B. Saunders, Philadelphia, Pa., 1990; pp 545-561.
17. Grindem, C.B. et al: Epidemiologic Survey of Thrombocytopenia in Dogs: A Report on 987 Cases. *Vet Clin Pathol* 20:38, 1991.
18. Hammer, A.S.: Thrombocytosis in Dogs and Cats: A Retrospective Study. *Comp Haematol Int* 1:181, 1991.
19. Harvey, J.W.; Rackear, D.: Experimental Onion-induced Hemolytic Anemia in Dogs. *Vet Pathol* 22:387, 1985.
20. Haurani, F.I. et al: Defective Reutilization of Iron in the Anemia of Inflammation. *J Lab Clin Med* 65:560, 1984.
21. Hegde, U.M.: Platelet Antibodies in Immune Thrombocytopenia. *Blood Rev* 6:34, 1992.
22. Helfand, S.C. et al: Immune-mediated Thrombocytopenia Associated with Solid Tumors in Dogs. *J Am Anim Hosp Assoc* 21:787, 1985.
23. Hoff, B. et al: Myelofibrosis: Review of Clinical and Pathological Features in Fourteen Dogs. *Can Vet J* 32:357, 1991.
24. Hubler, M. et al: Feline Neonatal Isoerythrolysis in Two Litters. *J Small Anim Pract* 28:833, 1987.

25. Jackson, M.L.; Kruth, S.A.: Immune-mediated Hemolytic Anemia and Thrombocytopenia in the Dog: A Retrospective Study of 55 Cases Diagnosed from 1969 through 1983 at the Western College of Veterinary Medicine. *Can Vet J* 26:245, 1985.
26. Jain, N.C.: *Essentials of Veterinary Hematology*. (N.C. Jain, ed.), Lea & Febiger, Philadelphia, Pa., 1993.
27. Jain, N.C.: Schalm's *Veterinary Hematology*, 4th Ed., Lea & Febiger, Philadelphia, Pa., 1986.
28. Jans, H.E. *et al*: Therapy of Immune-mediated Thrombocytopenia. A Retrospective Study of 15 Dogs. *J Vet Intern Med* 4:4, 1990.
29. Jonas, L.D., *et al*: Nonregenerative Form of Immune-mediated Hemolytic Anemia in Dogs. *J Am Anim Hosp Assoc* 23:201, 1987.
30. Kay, N.E.: Natural Killer Cells. *CRC Crit Rev Clin Lab Sci* 22:343, 1986.
31. Klag, A.R., *et al*: Idiopathic Immune-mediated Hemolytic Anemia in Dogs: 42 Cases (1986-1990). *JAVMA* 202:783, 1993.
32. Klag, A.R.: Hemolytic Anemia in Dogs. *Comp Cont Ed* 14:1090-1095; 1992.
33. Kuehn, N.F.; Gaunt, S.D.: Clinical and Hematologic Findings in Canine Ehrlichiosis. *JAVMA* 186:355, 1985.
34. Latimer, K.S.: Leukocytes in Health and Disease. *Textbook of Veterinary Internal Medicine*, 4th Ed. (S.J. Ettinger and E.C. Feldman, ed.). W.B. Saunders, Philadelphia, Pa., 1995; pp 1892-1929.
35. Latimer, K.S.; Meyer, D.J.: Leukocytes in Health and Disease. *Textbook of Veterinary Internal Medicine*, 3rd Ed. (S.J. Ettinger, ed.). W.B. Saunders, Philadelphia, Pa., 1989; pp 2181-2225.
36. Latimer, K.S.; Rakich, P.M.: Clinical Interpretation of Leukocyte Responses. *Vet. Clin. North Am.: Sm Anim Pract* 19:637, 1989.
37. Lewis, H.B.; Rebar, A.H.: *Bone Marrow Evaluation in Veterinary Practice*. Ralston Purina, St. Louis, Mo., 1979.
38. Madewell, B.R.: Hematological and Bone Marrow Cytological Abnormalities in 75 Dogs with Malignant Lymphoma. *J Am Anim Hosp Assoc* 22:235, 1986.
39. May, M.E.; Waddell, C.C.: Basophils in Peripheral Blood and Bone Marrow: A Retrospective Review. *Am J Med* 76:509, 1984.
40. McEwen, S.A. *et al*: Hypereosinophilic Syndrome in Cats: A Report of 3 Cases. *Can J Comp Med* 49:248, 1985.
41. Meyers, K.M. *et al*: Canine von Willebrand's Disease: Pathobiology, Diagnosis, and Short-term Treatment. *Comp Cont Ed* 14:13, 1992.
42. Neer, T.M.: Hypereosinophilic Syndrome in Cats. *Comp Cont Ed* 13:549, 1991.
43. Northern, J.; Tvedten, H.W.: Diagnosis of Microthrombocytosis and Immune-mediated Thrombocytopenia in Dogs with Thrombocytopenia: 68 Cases (1987-1989). *JAVMA* 200:368, 1992.
44. Reagan, W.J.; Rebar, A.H.: Platelet Disorders, *Textbook of Veterinary Internal Medicine*, 4th Ed. (S.J. Ettinger and E.C. Feldman, ed.). W.B. Saunders, Philadelphia, Pa., 1995; pp 1964-1976.
45. Reagan, W.J.: A Review of Myelofibrosis in Dogs. *Toxicol Pathol* 21:169, 1993.
46. Rebar, A.H.: Anemia. *Clinical Signs and Diagnosis in Small Animal Practice* (E.B. Ford, ed.). Churchill Livingstone, New York, N.Y., 1988.
47. Rebar, A.H.: Interpreting the Feline Hemogram. *Handbook of Feline Medicine*. Pergamon Press, Oxford, U.K., 1993.

- 
48. Rebar, A.H.; Metzger, F.: The Veterinary CE Advisor—Clinical Pathology for Small-animal Practitioners: Interpreting the Hemogram. *Veterinary Medicine* 90(6) (Suppl.):1-12, 1995.
  49. Shelton, G.H. et al: Hematologic Manifestations of Feline Immunodeficiency Virus Infection. *Blood* 76:1104, 1990.
  50. Tvedten, H. et al: Estimating Platelets and Leukocytes on Canine Blood Smears. *Vet Clin Pathol* 17:4-11; 1988.
  51. Weiser, M.G.: Erythrocyte Responses and Disorders: *Textbook of Veterinary Internal Medicine*, 4th Ed. (S.J. Ettinger and E.C. Feldman, ed.). W.B. Saunders, Philadelphia, Pa., 1995; pp 1864-1891.
  52. Weiser, M.G.: Erythrocytes and Associated Disorders. *Textbook of Veterinary Internal Medicine*, 3rd Ed. (S.J. Ettinger, ed.). W.B. Saunders, Philadelphia, Pa., 1989; pp 2145-2181.
  53. Wellman, M.L. et al: Lymphocytosis of Large Granular Lymphocytes in Three Dogs. *Vet Pathol* 26:158, 1989.
  54. Wilkerson, M.J., et al: Blood Type A and B in Two Cat Colonies in Washington State and a Clinical Transfusion Reaction. *Feline Pract* 19:22, 1991.
  55. Willard, M. et al: *Textbook of Small Animal Clinical Diagnosis by Laboratory Methods*, 2nd Ed. W.B. Saunders, Philadelphia, Pa., 1994; pp 11-80.
  56. Williams, D.A.; Maggio-Price, L.: Canine Idiopathic Thrombocytopenia: Clinical Observations and Long-term Follow-up in 54 Cases. *JAVMA* 185:660, 1984.



Nestlé Purina PetCare Company  
Checkerboard Square  
St. Louis, Missouri  
VET 6146